

Multi-staged approach for safe removal of Tentorial Meningioma – a case report

Dr. Aditya Mundada (Resident Neurosurgery)
Dept. of Neurosurgery,
DYPMCH

Guided by
Dr. Deepak Ranade
(Professor and Head, Neurosurgery)



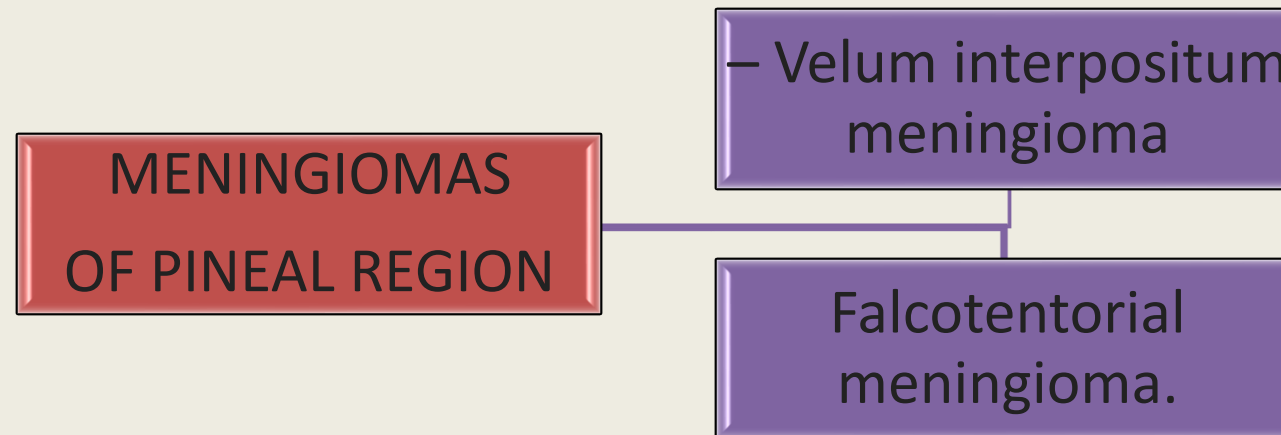
Introduction

Introduction

- The first reported case of tentorial meningioma was in 1833 which was done by Andraal who incidentally discovered a lesion attached to the tentorium. ^[1]
- Falcotentorial meningiomas are rare and comprise only 0.3-1.1% of all meningiomas.
- The term ‘falcotentorial’ applies to lesions located anterior to the junction between falx and tentorium.
- Lesions located at the posterior part of the junction are described as ‘peritorcular’ meningiomas.^[2]

Introduction

- Falcotentorial meningiomas have a dural attachment and invade the pineal region.



- Surgical treatment of these tumors is difficult and associated with a high morbidity and mortality. [4]

Introduction

- The tentorium has a simple structural design , however its edges are close to the brainstem and its role in the venous drainage of the brain makes surgical approach a challenge even for experienced neurosurgeons.[5]
- The choice of surgical strategy for such lesions is not straightforward and depends on many factors such as exact location, familiarity with the complex anatomy, and experience of the neurosurgeon.[6]



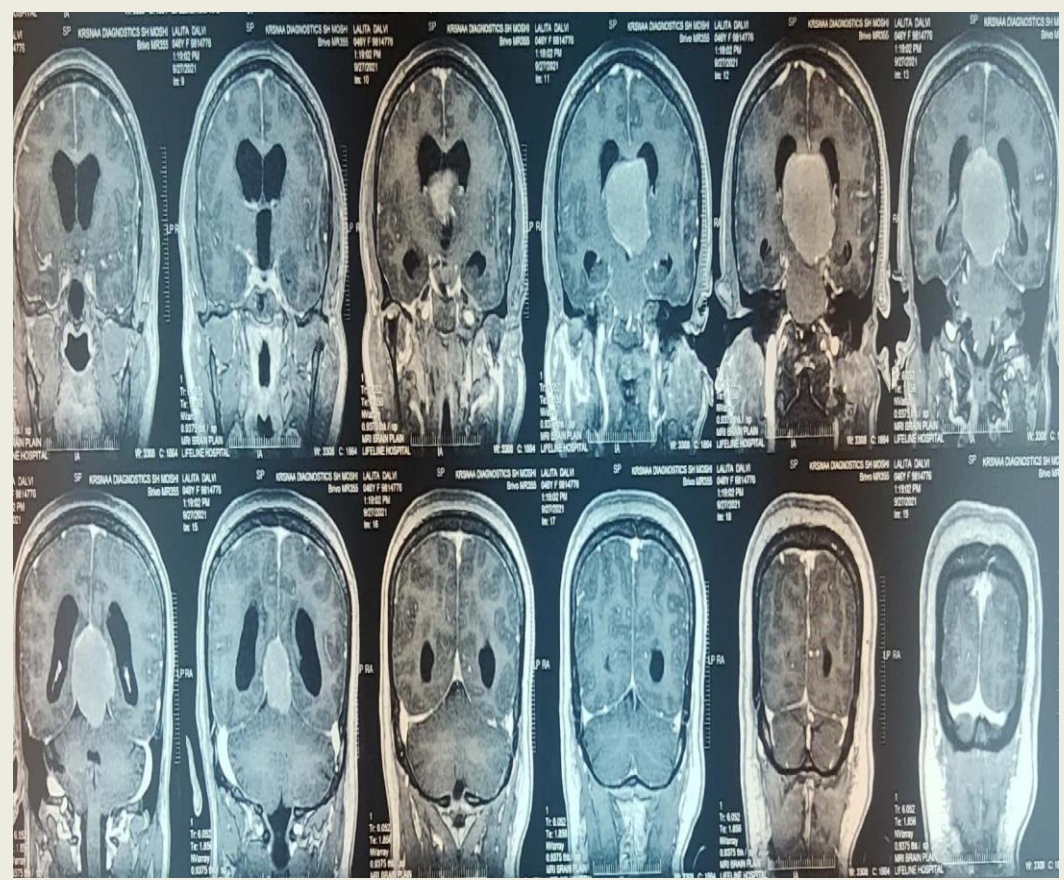
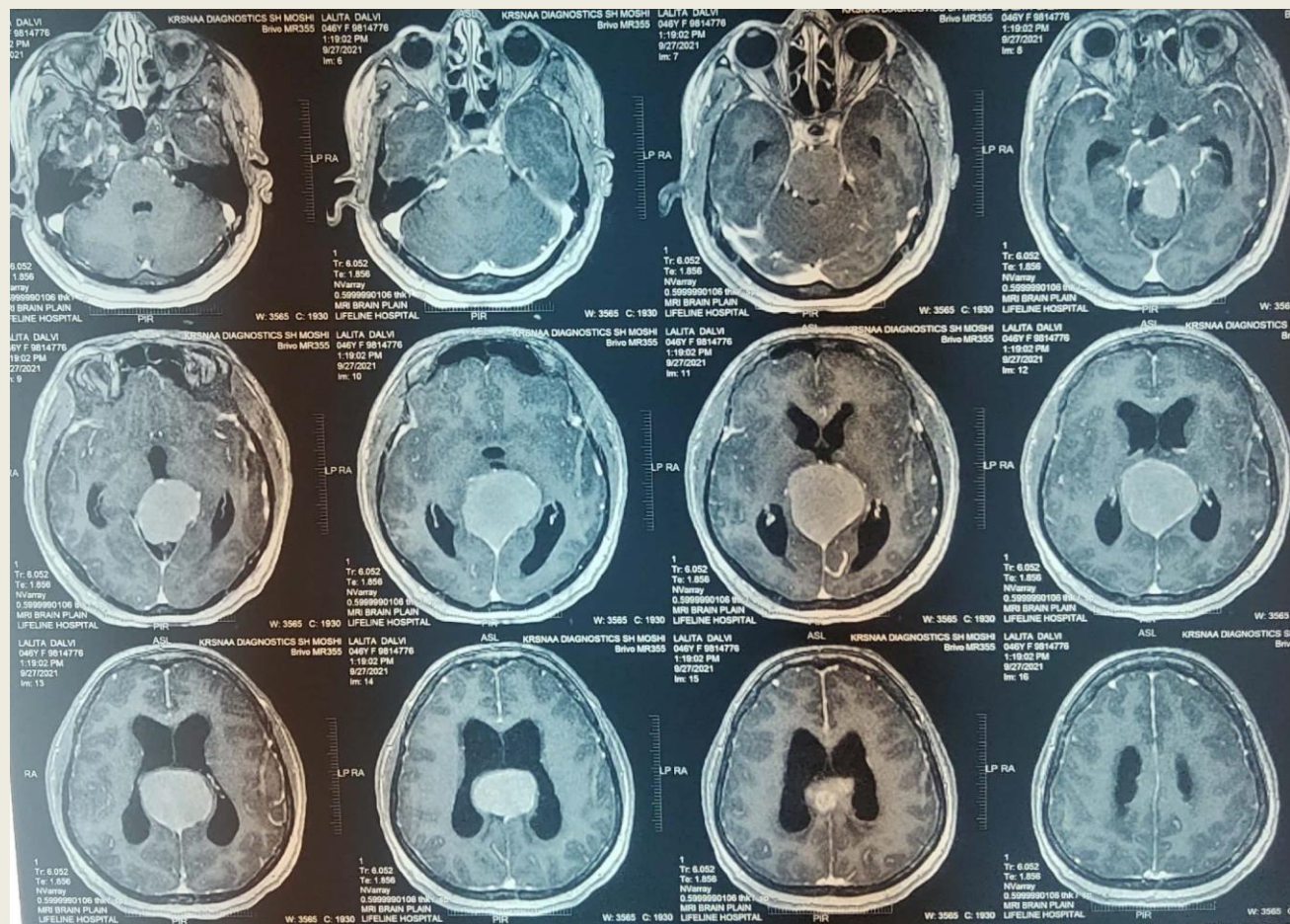
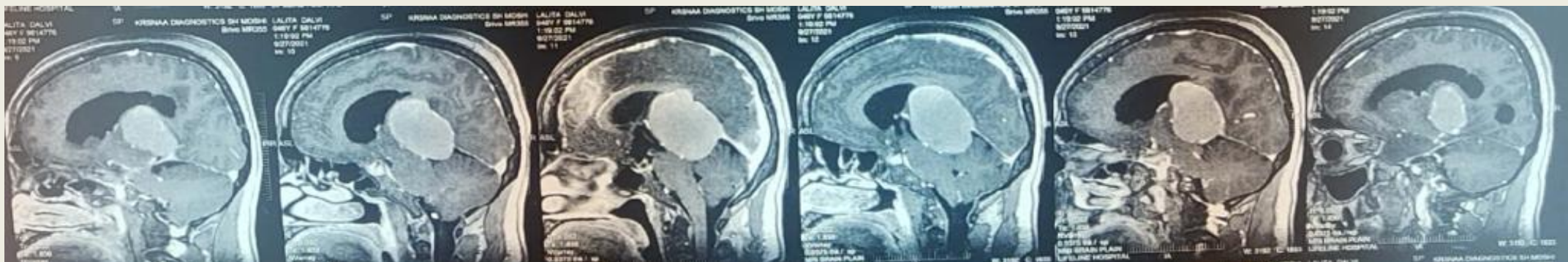Case Report

Case Report

- 46 year old female came to our institute with complaints of gradually intensifying headache since 3 months which had aggravated over a period of 5 days.
- She complained of imbalance while walking and urinary incontinence since 1 week. Patient also had a history of one episode of seizure.
- On examination , she was conscious and oriented to time , place and person. Vitals were stable and pupils were equal and reactive to light bilaterally.
- She had an ataxic gait with imbalance more towards to the left side. Power was preserved in all 4 limbs.
- Rombergs test was positive. There were no ocular manifestations but fundus examination revealed papilloedema.

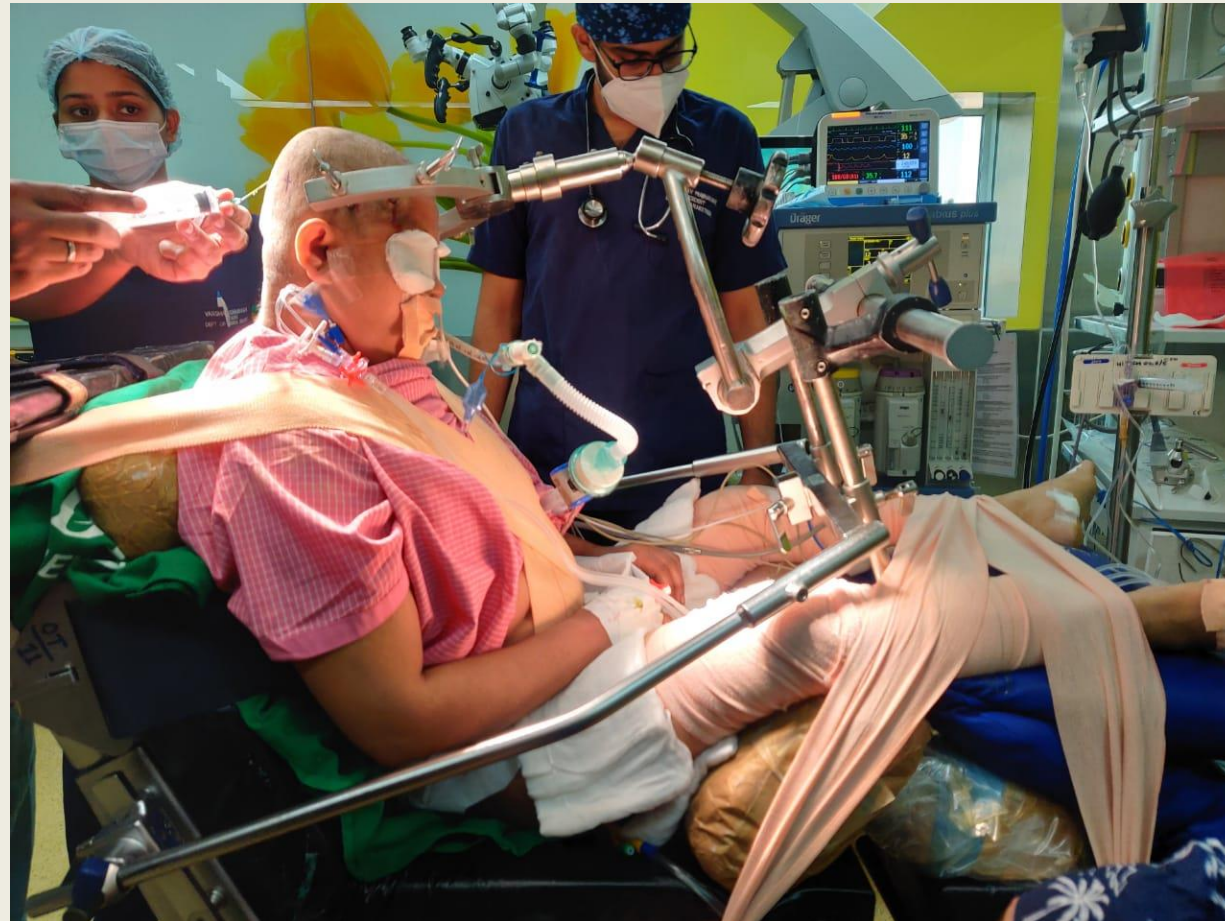Investigations

- MRI Brain with contrast was done which showed a large, well circumscribed, lobulated , midline, extra-axial lesion attached to the posterior third of the falx and the anterior lip of the tentorium.
- Lesion caused compression of the aqueduct of sylvius, invaded the quadrigeminal cisterns with mass effect on bilateral thalami, pineal gland, midbrain, pons and cerebellum.
- It measured about 5.1 x 4 x 4.2 cm (CC x AP x TR). On post-contrast study, there was strong homogenous enhancement.
- An MR Angiography and Venography was performed to get a clear picture of the displacement of the arteries and the inferior sagittal sinus, which was displaced upwards, and anteriorly.



Patient Positioning and Intra-Operative findings

- Patient was positioned in Sitting position which is mostly used for posterior fossa surgeries.

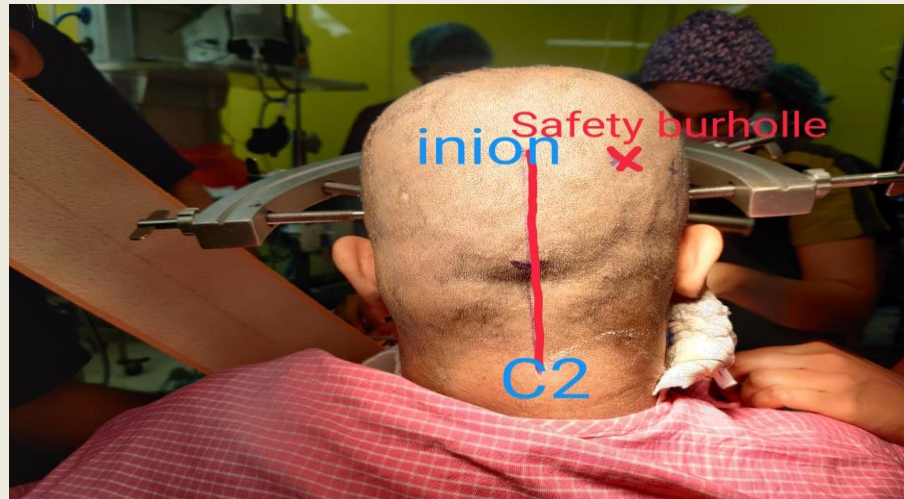


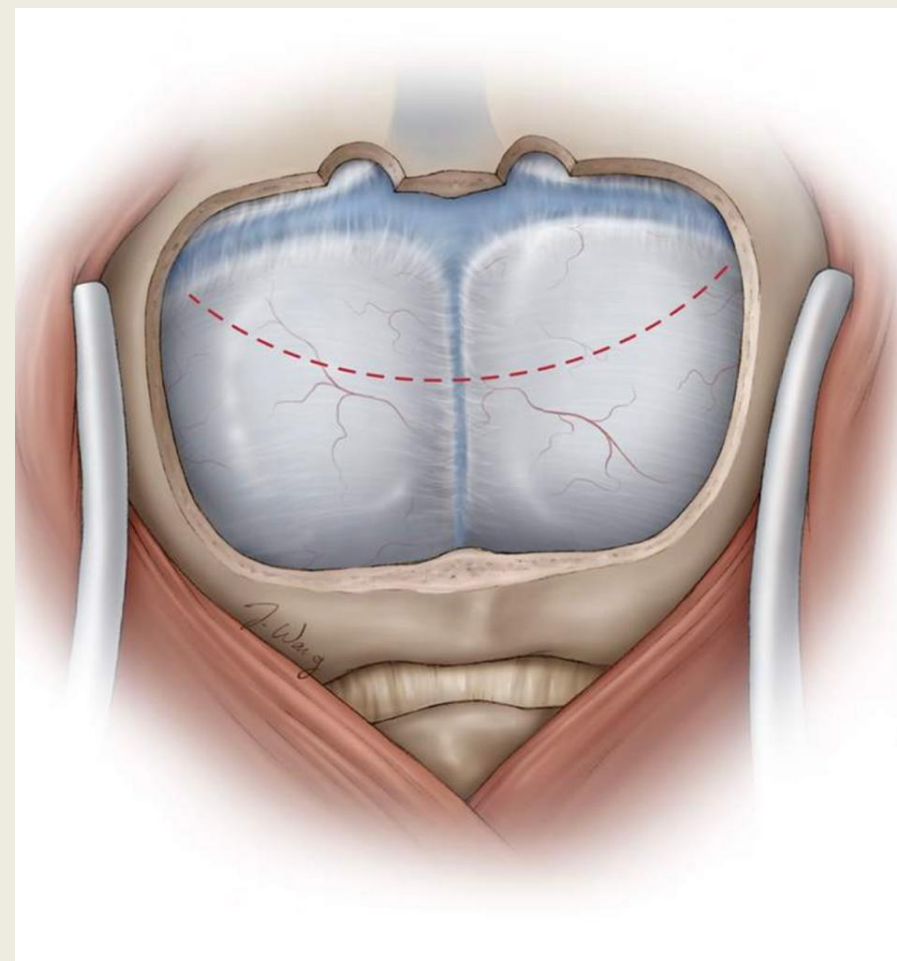
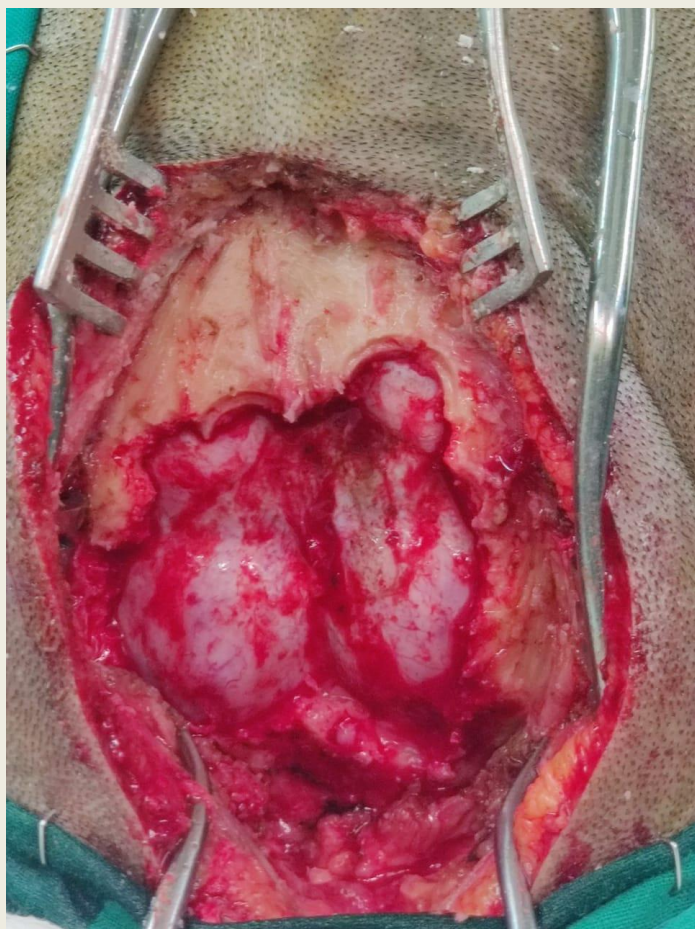
Advantages and disadvantages of sitting position

Benefits	Risk factors
Optimal surgical exposure for posterior fossa surgeries	Risk of venous air embolism and paradoxical air embolism
Reduced risk of tissue retraction injury and cranial nerve damage	Bradycardia or cardiac arrest due to brainstem manipulations
Improved cerebral venous drainage and less blood loss	Pneumocephalus, subdural hematoma and quadriplegia
Improved ventilation due to downward shift of diaphragm.	Postural hypotension due to decrease in venous return
Patients airway accessible to anaesthesiologist.	

Patient Positioning and Intra-Operative findings

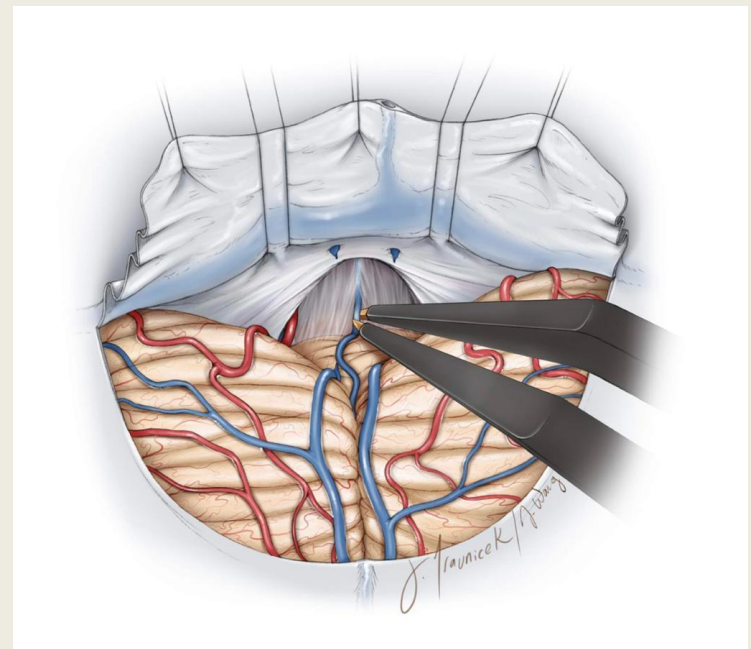
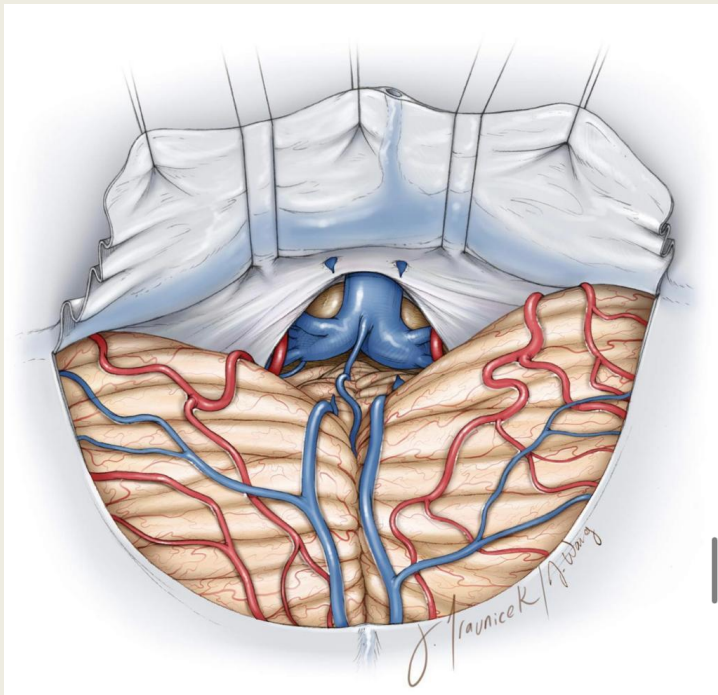
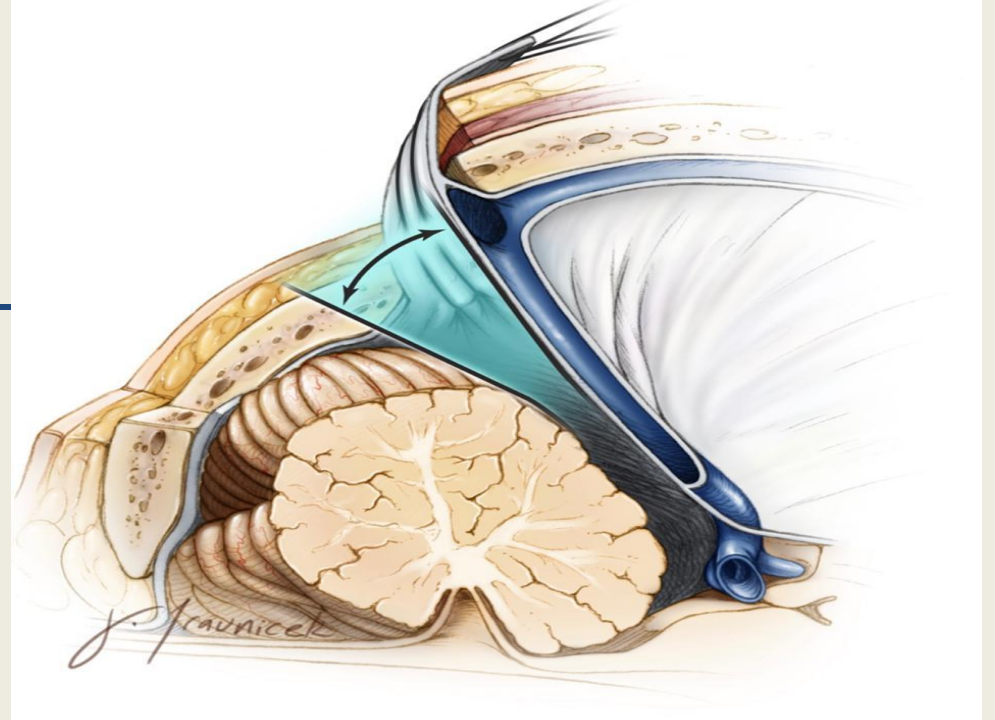
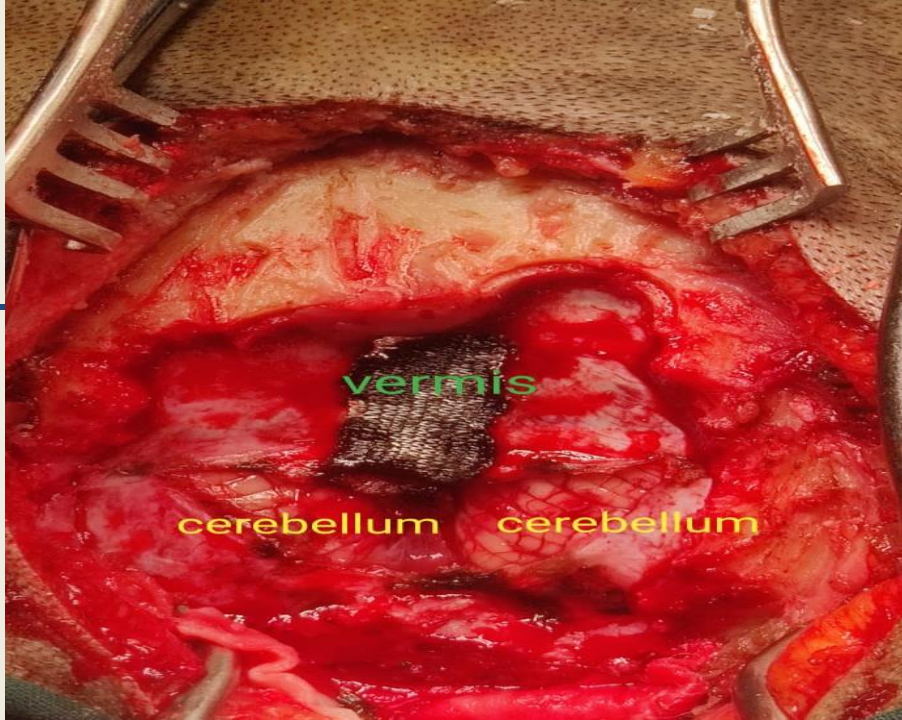
- Surgery was done under general anaesthesia. Patient was in sitting position
- Steins approach was deployed with plan to excise whole of the tumour.
- Incision was marked frominion to C2 level. Local anesthesia was given and incision was taken. A safety burrhole was done for CSF drainage
- Suboccipital craniotomy was done with exposure of superior nuchal line to C1





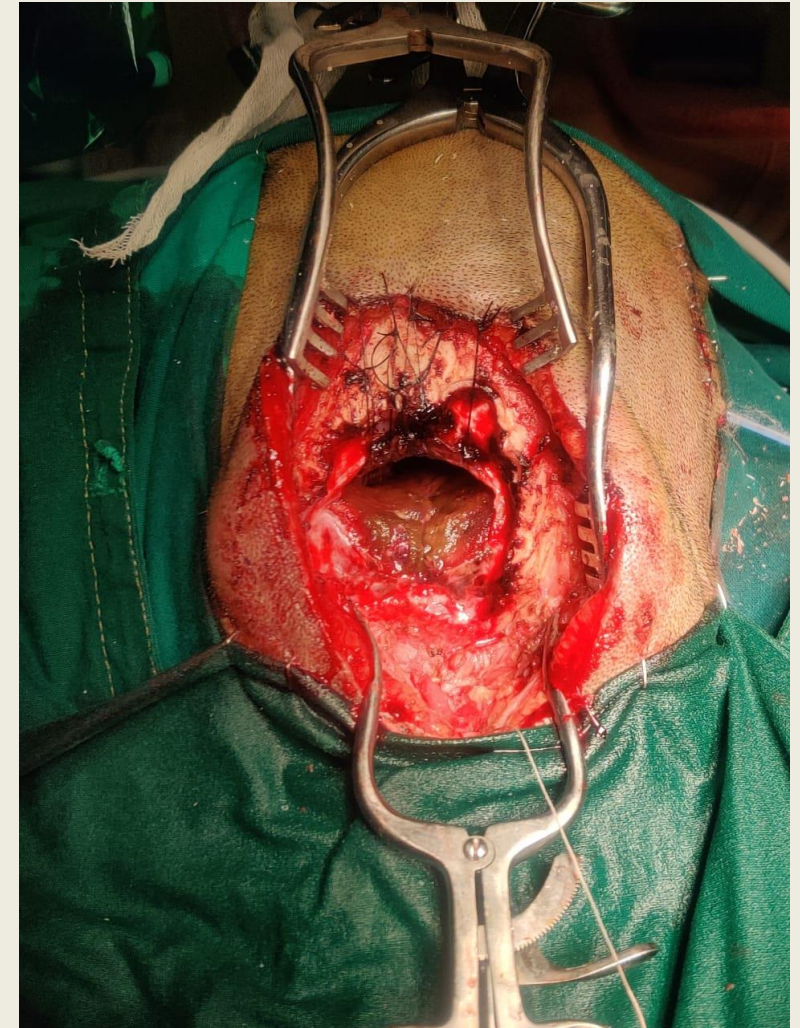Patient Positioning and Intra-Operative findings

- Transverse sinus was exposed and dura cut with base towards the transverse sinus.
- Occipital sinus was tied. The cerebellar lobes, vermis and midline vermian bridging veins were exposed.
- The above veins were coagulated and cut. Cerebellum retracted downwards.
- Tumour was exposed



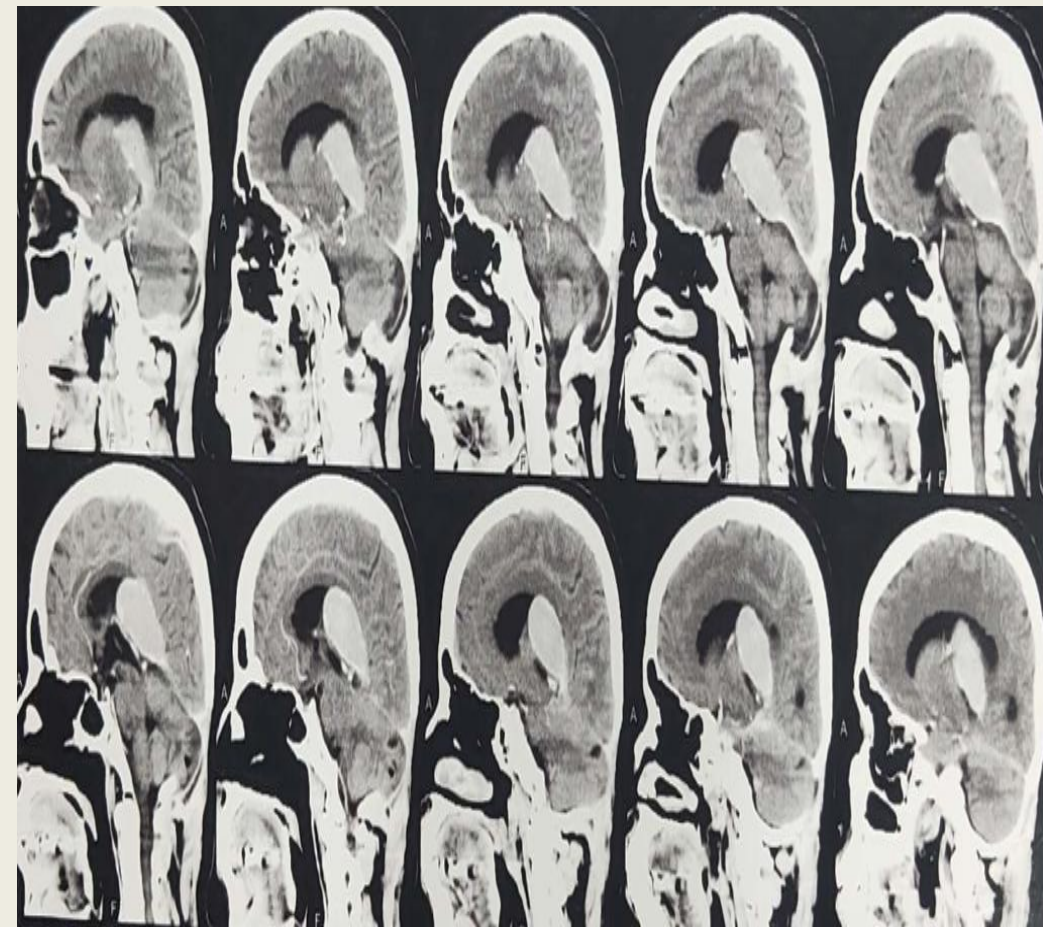
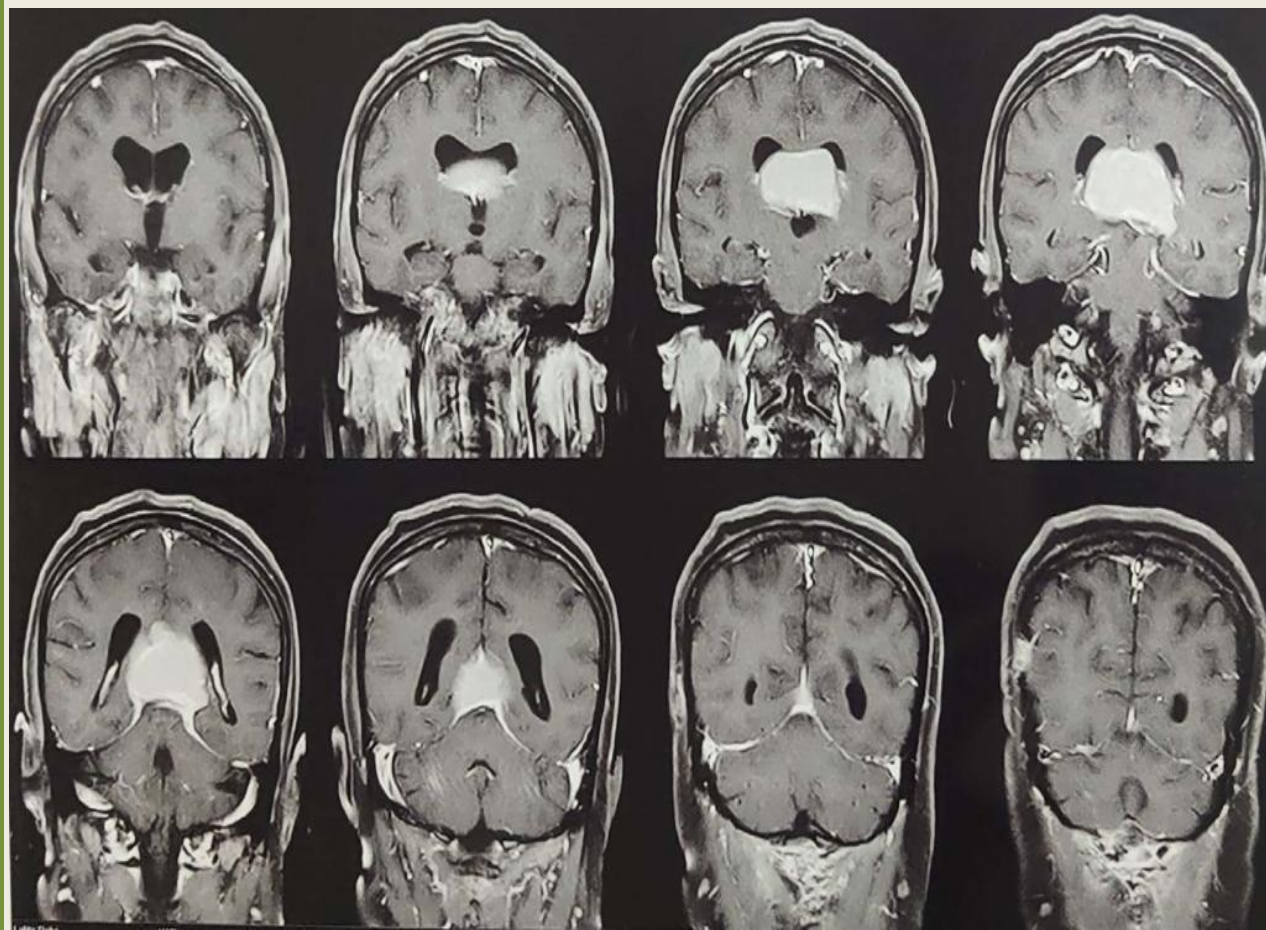
Patient Positioning and Intra-Operative findings

- The tumor was devascularised, debulked and thereafter the capsule was dissected off from the anteriorly placed collicular plate and upper brain stem.
- Attempts to approach the supratentorial portion by incising the tentorium were unsuccessful as the required trajectory was far too acute.
- The supra tentorial portion would have to be approached by a more cranial trajectory, and hence it was decided to tackle that portion at a second stage.



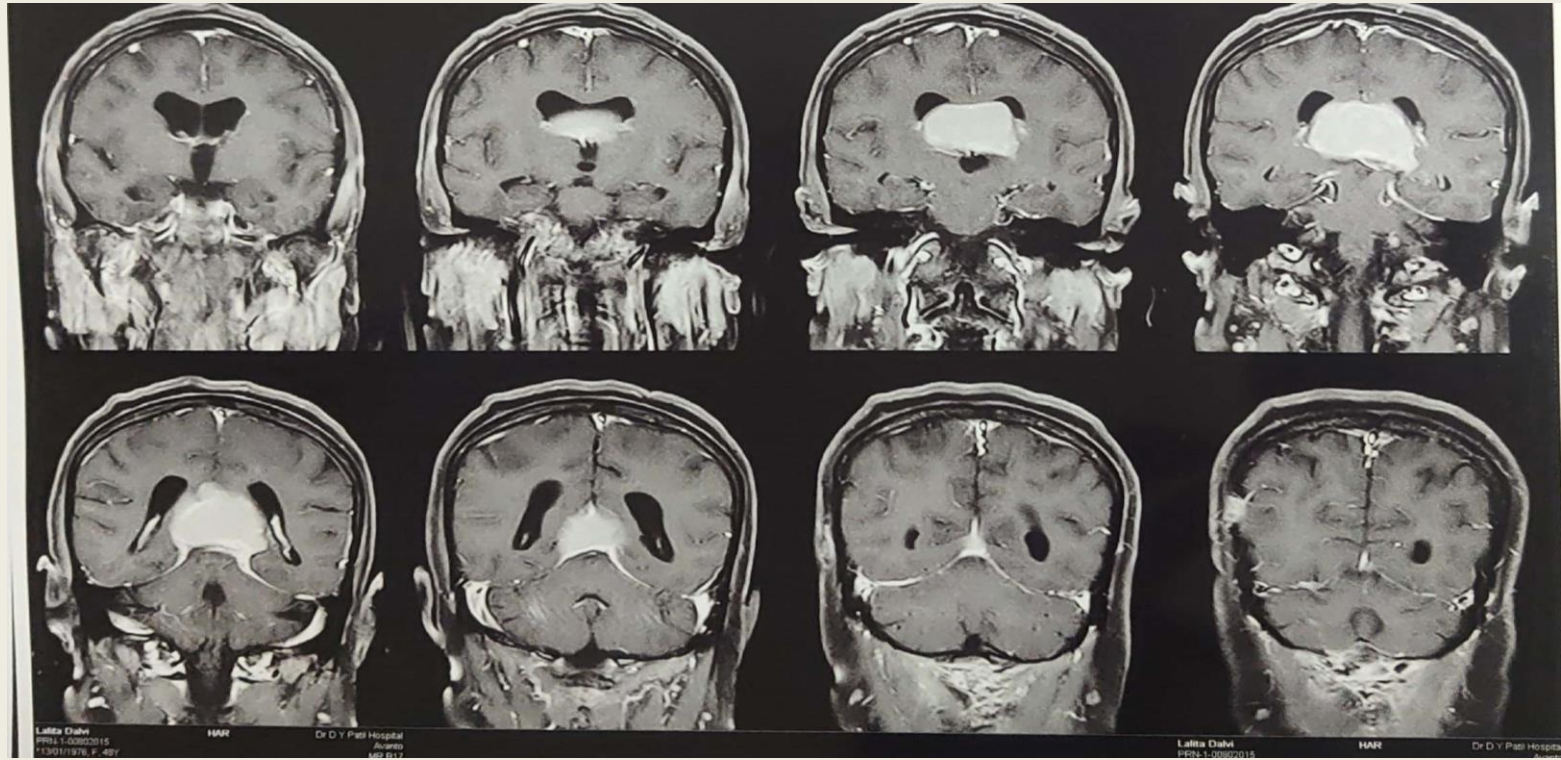
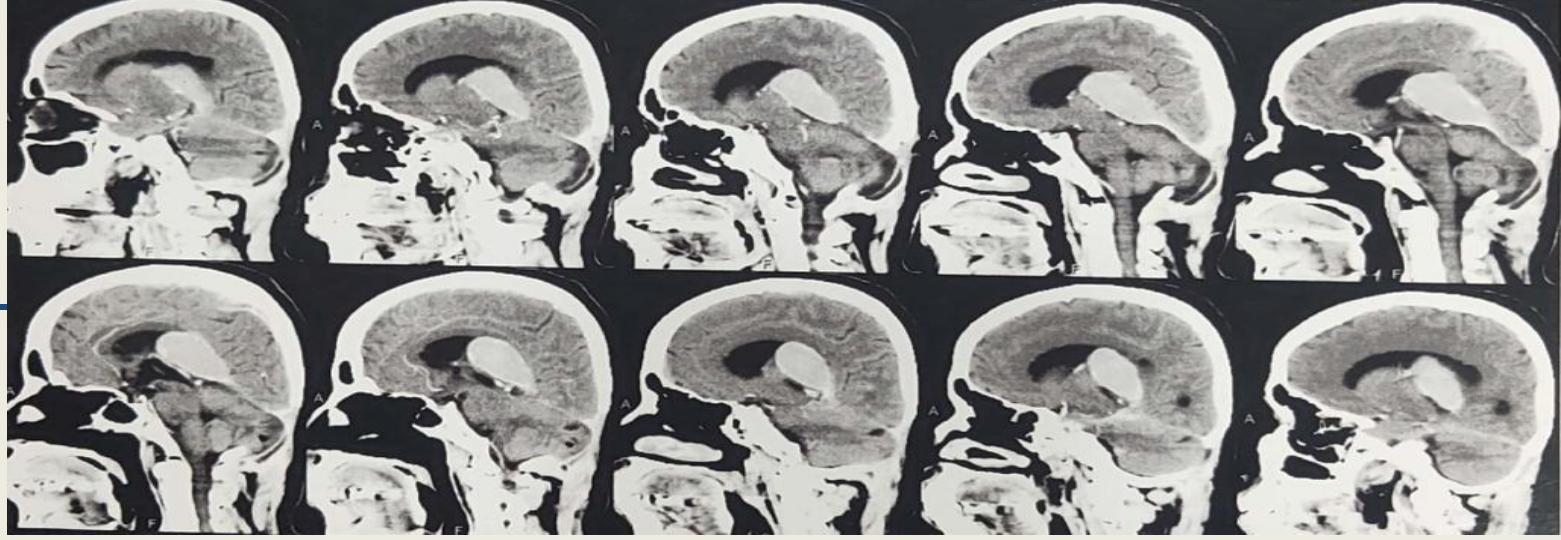
-
- The Patient recovered well after an uneventful post operative period. Post-op imaging confirmed the limitations of our approach to tackle the residual supratentorial tumor.
 - Histology revealed the tumor to be a Grade 1 – meningothelial meningioma.
 - Patient was discharged on POD 7

Postoperative scan showing complete removal of infratentorial part of meningioma after 1st surgery



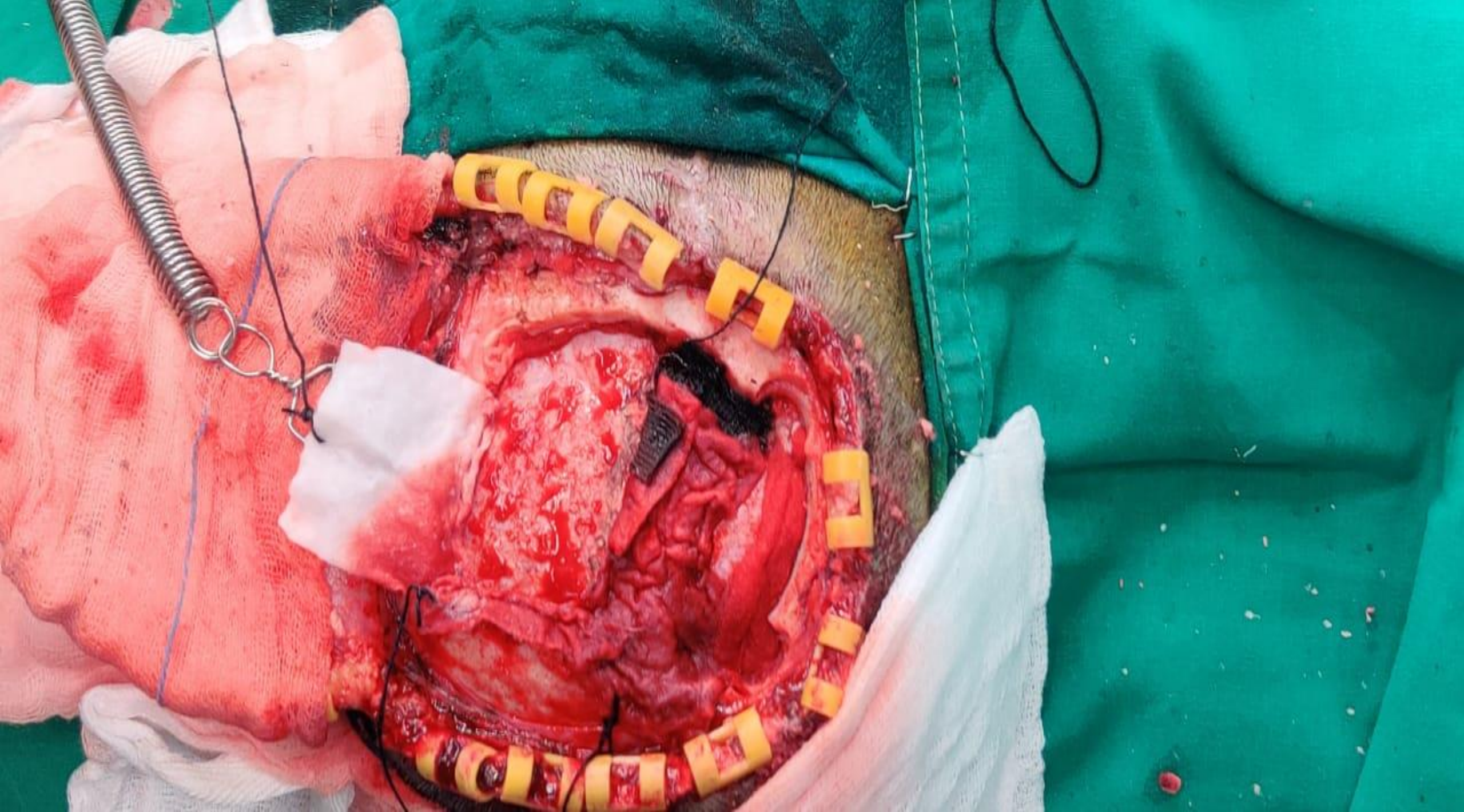Investigation done during 2nd admission

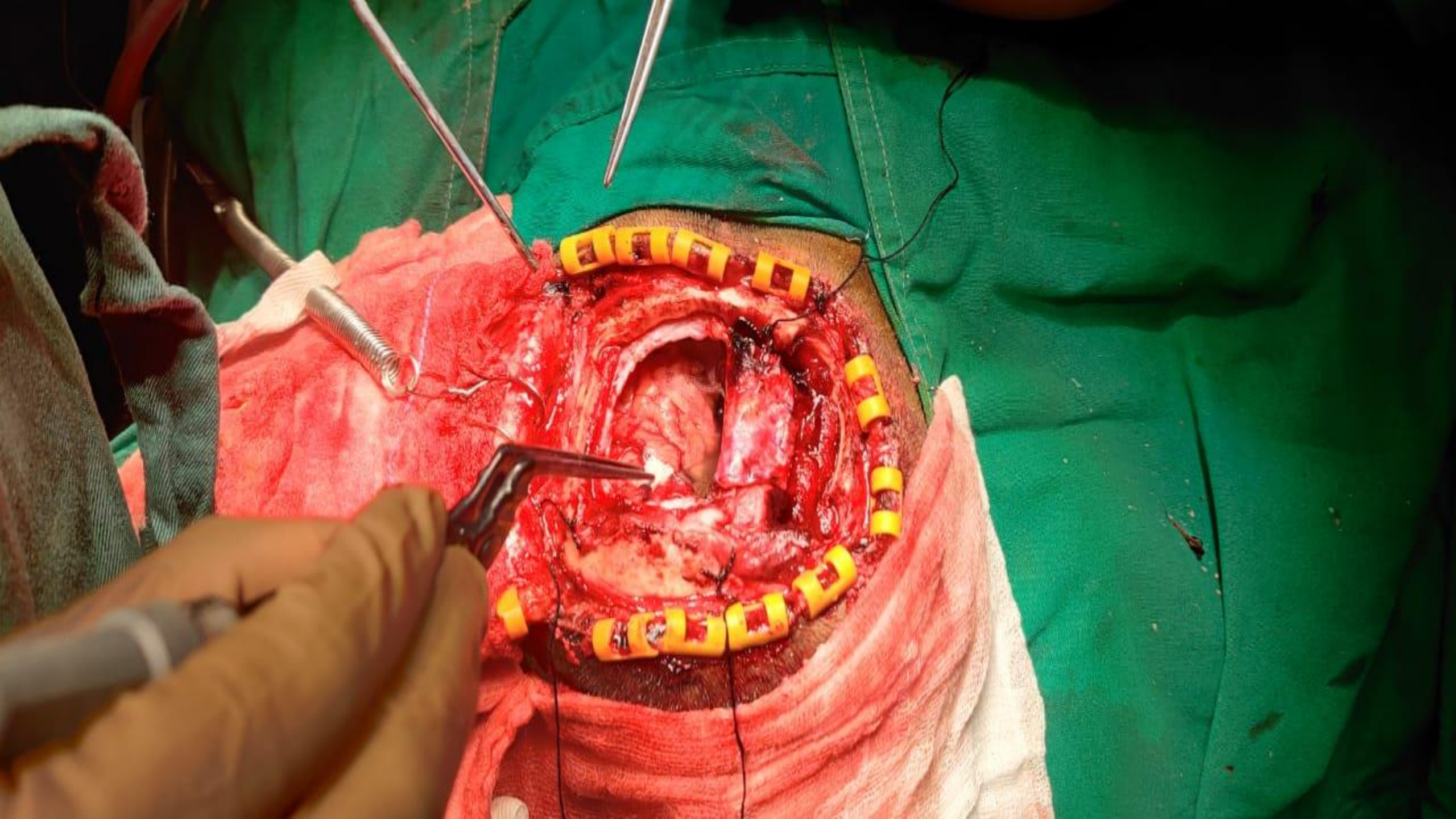
- Patient was readmitted after 6 weeks for the second surgery.
- Pre operative MRI Brain contrast scan revealed a midline, extra-axial lesion attached to posterior falx indenting the posterior 3rd ventricle of size 3.1x4.1x4.2cm (CC x AP x TR) with strong post contrast enhancement.



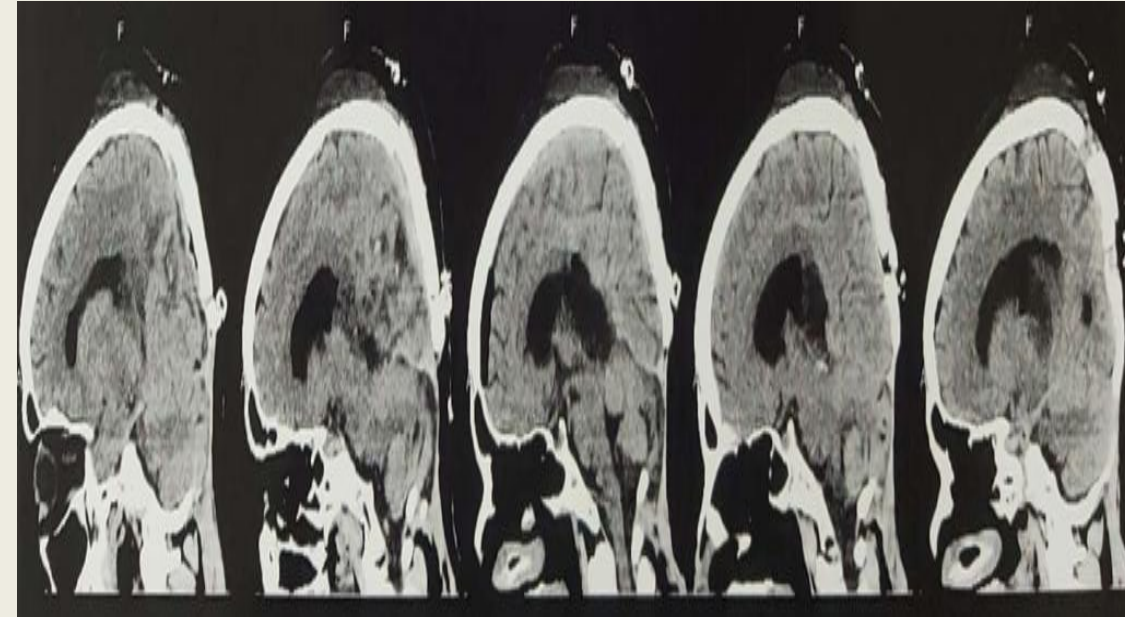
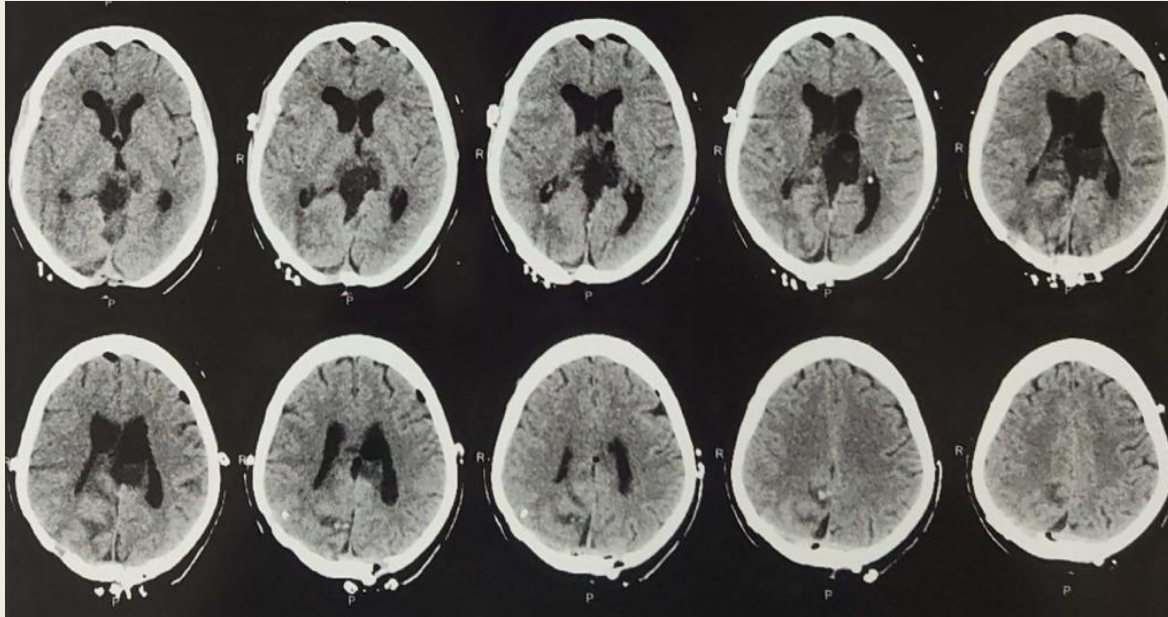
Operative findings in 2nd stage

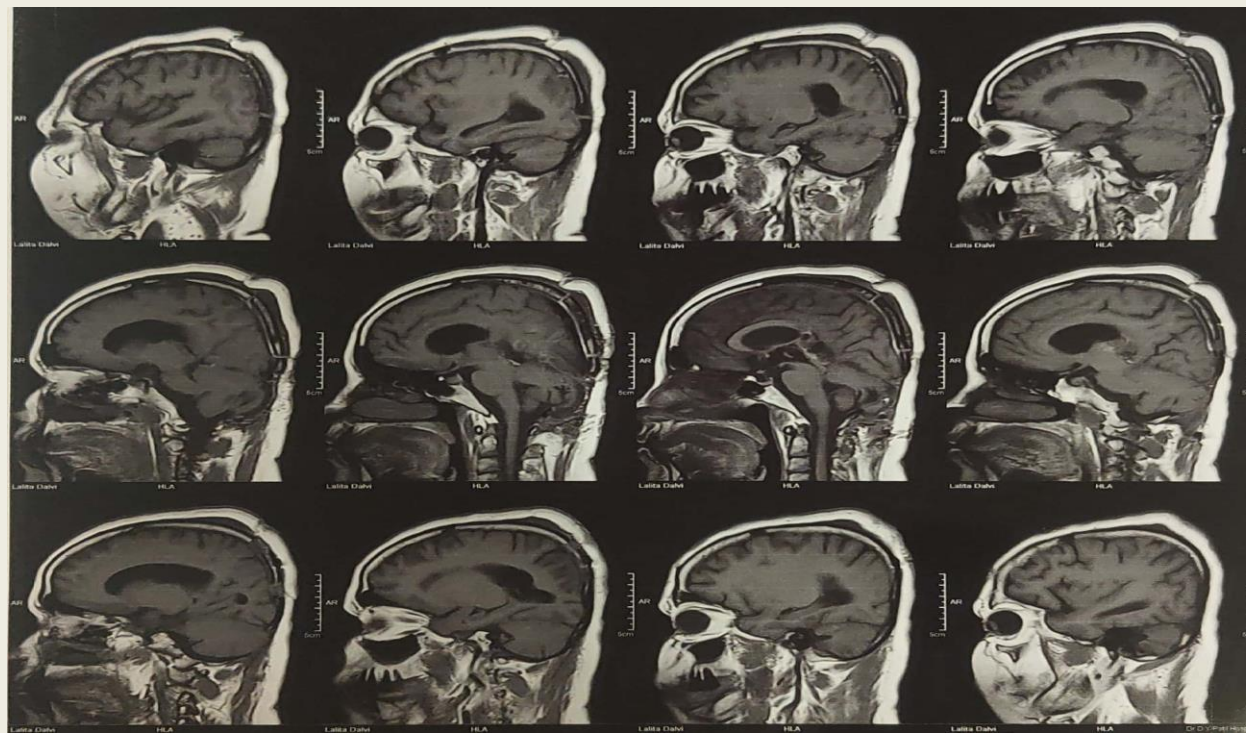
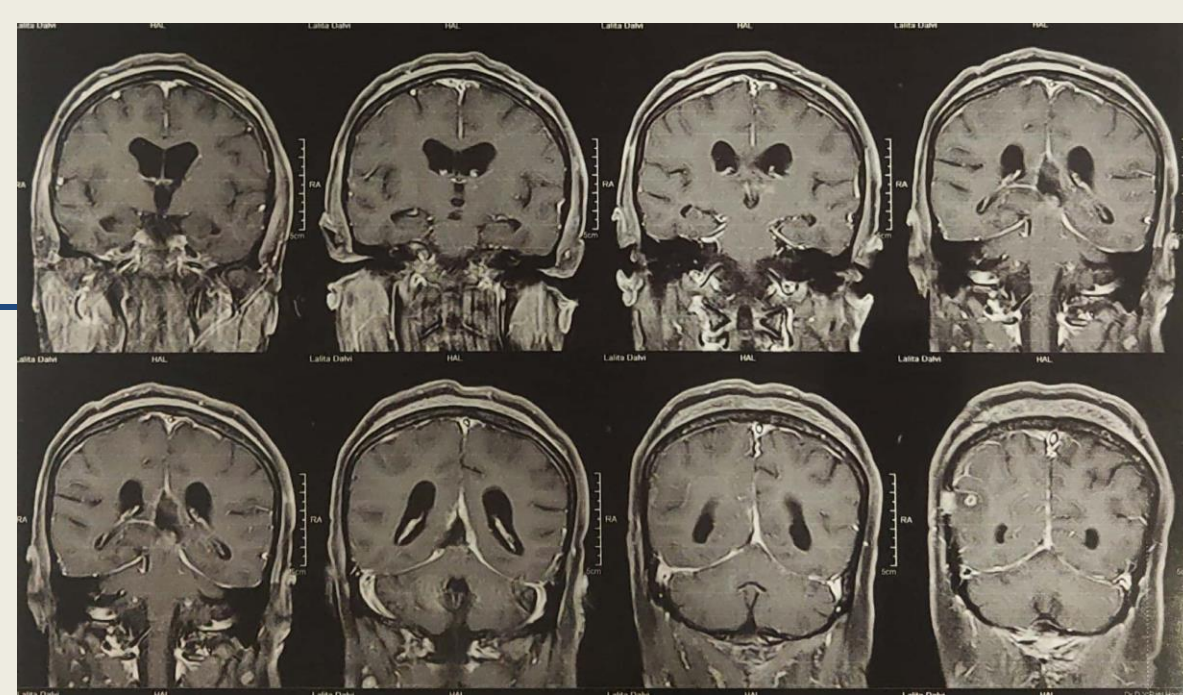
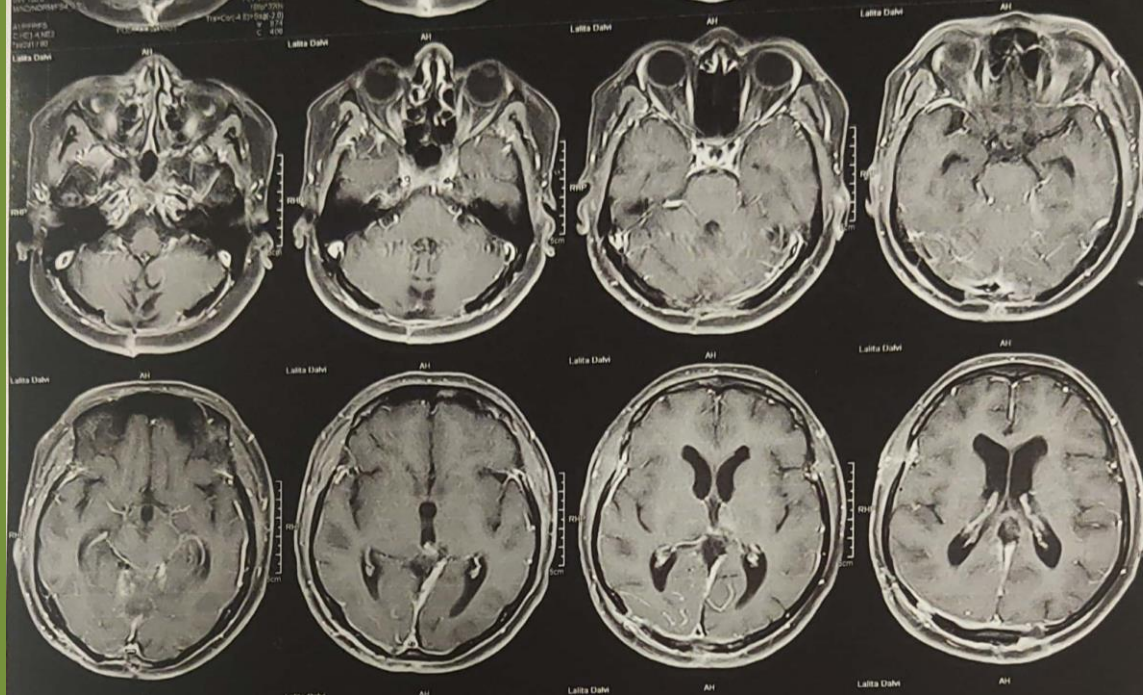
- Patient was taken up for surgery in prone position under GA.
- Parietal craniotomy was done
- tumor was approached through posterior interhemispheric transfalcine approach. The tumor was firm and hard.
- Tumor was devascularised and debulked using CUSA.
- The falx was incised and Simpsons Grade 1 gross total tumor resection was achieved.





Postoperative CT after 2nd stage surgery showing complete removal of supratentorial as well as infratentorial extension of meningioma





-
- Patient was extubated and shifted to ICU for neuromonitoring. Patient was discharged on POD 7.
 - Post-op scan showed gross total excision of the tumor with no evidence of hydrocephalus.
 - On follow up after 3 months, patient is ambulatory without support with no complaints of headache and imbalance while walking.





Discussion

Discussion

- Falcotentorial meningiomas are a rare and heterogenous group of tumors. [5]
- The largest series was only of 15 cases reported by Qiu et al in 2014. [2]
- It is a difficult category of meningiomas due to interdigitating cranial nerves , arterial tree and venous drainage. Complication rates are high and are reported upto 35% in early records. 1.8% mortality rate was reported by Wagner et al. [6]
- Two classification systems have been described for falcotentorial meningiomas. One of these was by Asari et al in 1995 which is based on tumor projection and classifies them as anterior , posterior , superior and inferior types.
- The other classification is by Bassiouni et al in 2008 which classifies them according to tumor base location and is divided as : type 1 (between the 2 leaflets of falx) , type 2 (middle inferior tentorial surface) , type 3 (unilateral tentorium) , type 4 (unilateral falx or straight sinus). [2]

Discussion

- Signs and symptoms of increased intracranial pressure are commonest finding followed by cerebellar ataxia.
- Occurrence of psychiatric disorders, gait disturbances and bladder incontinence has also been described in these lesions. [7]
- The location of the tumor, size and direction of growth are all important to determine the surgical approach. Various surgical approaches have been described for falcotentorial meningiomas which include infratentorial supracerebellar, occipital transtentorial, suboccipital and combined supratentorial and infratentorial approaches.[3]
- Combined supra/infratentorial-transsinus approach and occipital bitranstentorial/falcine approach could be advantageous for removal of large falcotentorial meningiomas during a single sitting , however blind spots remain around the skeletonized straight sinus and galenic venous system. [8]

Discussion

- Incision on the tentorium can be challenging due to high vascularity of the region which is increased in presence of the tumor. The dome of the tumor is accessed at the end of surgery and is a blind spot for the surgeon and this might lead to vessel injury at the dome of the tumor. [9]
- Choice of surgical approach for each case is based on the best strategy to attack the tumor and to avoid damaging the neighbouring structures. [6]
- For these lesions it has been rightly said ‘insistence to complete removal is not always necessarily the best judgement’[7] As these tumors are biologically benign, surgical damage to surrounding vital neurovascular structures should be avoided by not adopting an aggressive simultaneous , multi-directional strategy but rather a multi-staged , multi-directional strategy.
- Multi-staged and multi-directional strategy is an excellent choice for safe removal of the challenging lesions, especially ones which are more than 4cm. [8] Staged surgery is hence considered a reasonable option for complete removal of complex falcotentorial meningiomas.

Discussion

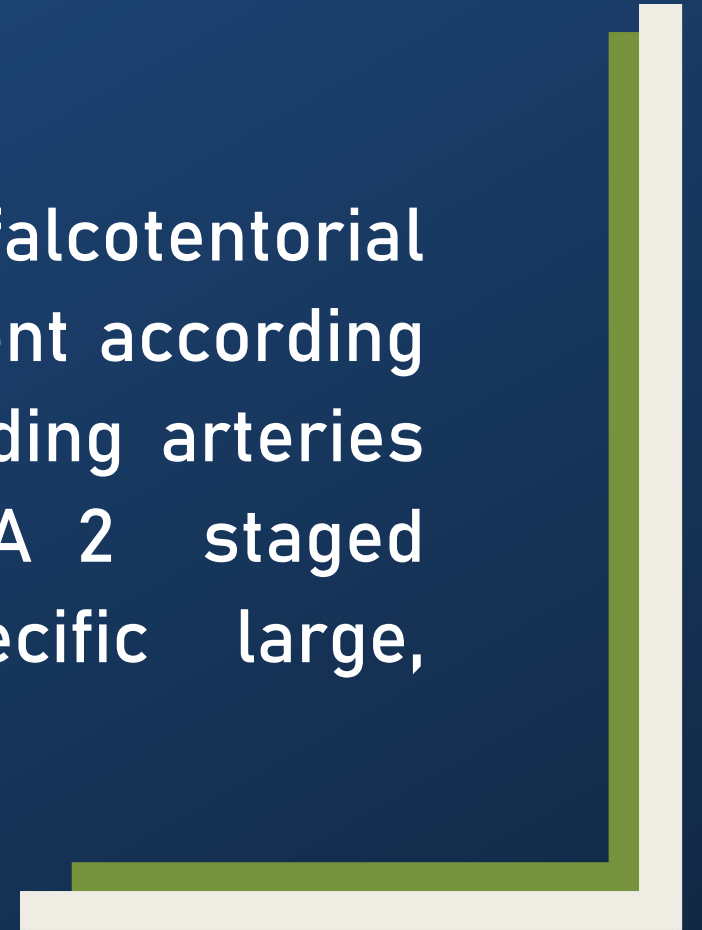- Each approach is used within the safe limits of the working angle. Instead of extending the existing approach which could damage critical structures due to over-retraction, the remaining parts of tumor can be safely removed by a separate approach by a more favourable trajectory.[2]
- It is also observed that there is less tumor bleeding during the second operation due to previous devascularisation and easier dissection of the reduced tumor from surrounding vital structures without causing deep venous injury.[8]
- The supracerebellar infratentorial approach is usually considered before occipital transtentorial/transfalcal as the infratentorial space is naturally larger than the supratentorial, especially in presence of space-occupying lesions. [2]
- This case is being reported to underline the importance of a delayed 2 stage approach to excise this complex genre of Falco tentorial meningiomas which invade the supra and infra tentorial compartments.

Discussion

- Some tumors may not be amenable to total excision in a single sitting. The delayed second stage makes the second approach easier as the post operative oedema is completely resolved, and facilitates retraction.
- The single stage surgery often times mandates longer duration of surgery, increasing the morbidity of anaesthesia, and complications like hypothermia and acid base imbalance due to prolonged IPPR.

CONCLUSION

Surgical approach for these complex falcotentorial meningiomas should be tailored to each patient according to origin and direction of tumor growth, feeding arteries and surrounding venous drainage system. A 2 staged approach is definitely indicated and for specific large, complex falcotentorial meningiomas.



References

1. Castro ID, Christoph DH, Landeiro JA. Combined Supra/ Infratentorial approach to tentorial meningiomas. Arq Neuropsiquiatr 2005;63(1):50-54
2. Zhao X, Belykh E, Przybylowski C, Moreira L, Gandhi S, Meybodi A, et al. Surgical treatment of falcotentorial meningiomas: a retrospective review of a single-institution experience. J Neurosurg 2019;1-13.
3. Hong C, Hong J, Park H, Moon J, Chang J, Lee K, Park S. Surgical treatment of falcotentorial meningiomas. Yonsei Med J 2016;57(4):1022-1028.
4. Majchrzak K, Tymowski M. Surgical treatment of the tentorial and falco-tentorial junction meningiomas. Minim Invas Neurosurg 2009;52:93-97.
5. Aguiar P, Tahara A, Almeida A, Kurisu K. Microsurgical treatment of tentorial meningiomas: report of 30 patients. Surg Neurol Int 2010;1:36.
6. Soffar H, Shimy M, Al-Shami H, Salah A. Surgical management of tentorial meningiomas: case series. The Egyptian Journal of Neurology, Psychiatry and Neurosurgery 2021;57(86):1-6.
7. Zaater A, Refaat M. Surgical management of tentorial meningiomas: analysis of 14 case experience. Egyptian Journal of Neurosurgery 2014;29(1):39-44.
8. Otani N, Mori K, Wada K, Tomiyama A, Toyooka T, Takeuchi S. Multistaged , multidirectional strategy for safe removal of large meningiomas in pineal region. Neurosurg Focus 2018; 44(4):1-7.

References

10. Ansari S, Young R, Bohnstedt B, Cohen-Gadol A. The extended supracerebellar transtentorial approach for resection of medial tentorial meningiomas. *Surgical Neurology International* 2014;5:35.
11. Qin C, Wang J, Long W, Xiao K, Wu C, Yuan J et al. Surgical management of tentorial notch meningioma guided by further classification : a consecutive study of 53 clinical cases. *Front Oncol* 10:609056.

THANK YOU

