



# Unwind

Dr. Pranay Penmetsa

Junior Resident (JR2)

Dept. Of Emergency Medicine


Under the guidance of

Dr. Varsha S. Shinde

Professor and Head of Department

Dept. of Emergency Medicine


- 
- 
- A 16 year old boy brought to the Emergency Department in an unresponsive state for the past 10 min

- 
- Patient had no palpable carotid pulse and hence CPR was started immediately as per ACLS protocol.
  - Patient connected to cardiac monitors and rhythm was asystole.
  - ROSC achieved after 20 min of CPR



# Primary Survey post ROSC

- Airway: Secured with ETT 8.0
- Breathing:
  - Respiratory Rate: 33cpm,
  - Saturation not recordable on pulse-oximetry

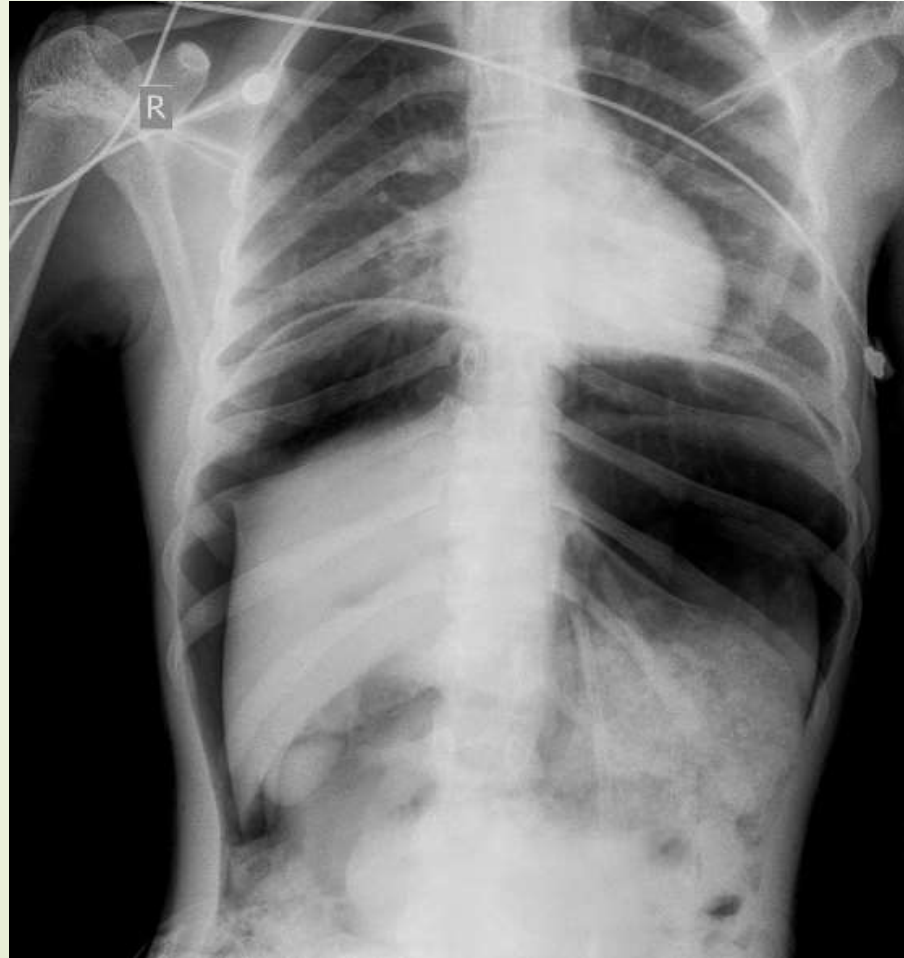- 
- Circulation:
    - Heart Rate: 160 bpm,
    - BP: Not recordable on dual pressor support (Noradrenaline and Vasopressin)
  - Disability: GCS 3/15, b/l dilated sluggishly reactive pupils
  - Exposure: Distended abdomen, partially relieved after placing ryles tube.



# Primary Adjuncts

- ECG: Sinus Tachycardia
- ABG: Severe Metabolic and Lactic Acidosis
- XRay:

# Portable Bedside XRay









## Secondary Survey

- A 16 year old boy was complaining of early morning epigastric pain for the past 15 days, intermittent burning type of pain, no aggravating factors but relieves on taking antacids, exaggerated since last night



- 
- Patient went to a local clinic who had given PPI and had referred for a USG Abdomen plus Pelvis the previous night.
  - Patient was on his way to get a scan but had become unresponsive on the way and was brought to DYPMCH within 10 minutes.



- 
- NO Allergies
  - H/o taking over the counter antacids for past 15 days to relieve pain.
  - NO significant Past Medical or Surgical History


- 
- 
- Last Meal was last night
  - Patient was observing a fast daily for past 15 days during the period of Ramadan



## Secondary Survey

- NO Pallor, Icterus, Cyanosis, Clubbing, Lymphadenopathy, Edema
- Abdominal Examination revealed uniformly distended tense abdomen, Tympanic note heard, Bowel sounds were absent. Normal digital rectal examination.

- 
- 
- CVS: S1 S2 heard
  - RS: b/l Vesicular Breath Sounds heard, no added sounds
  - CNS GCS 3/15, b/l dilated sluggishly reactive pupils

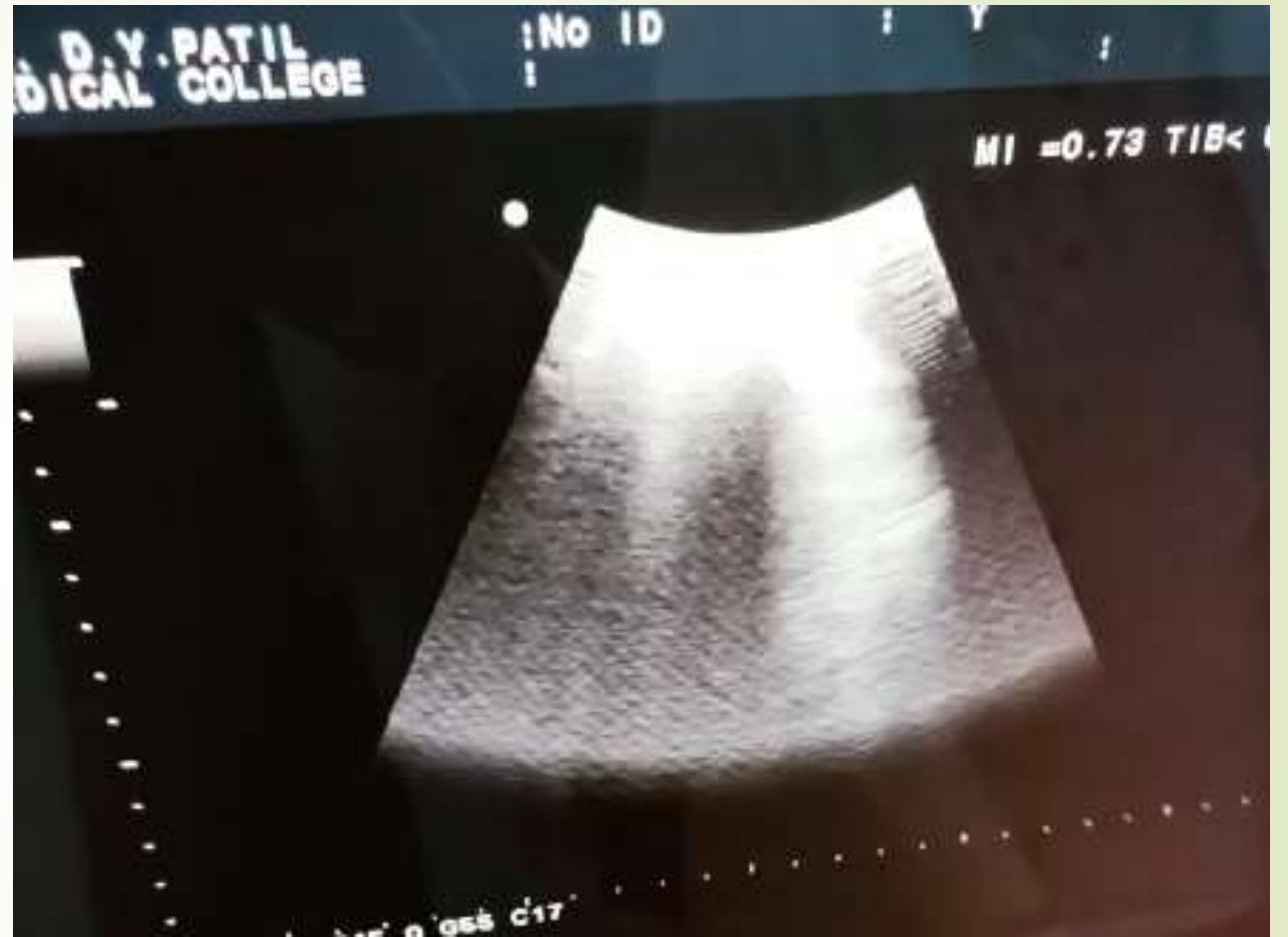- 
- A provisional diagnosis of Hollow viscus perforation with Abdominal Compartment Syndrome secondary to Tension Pneumoperitoneum



# Course

- General Surgeon was informed immediately.
- Bedside USG Abdomen Plus Pelvis was performed.

# Bed Side USG

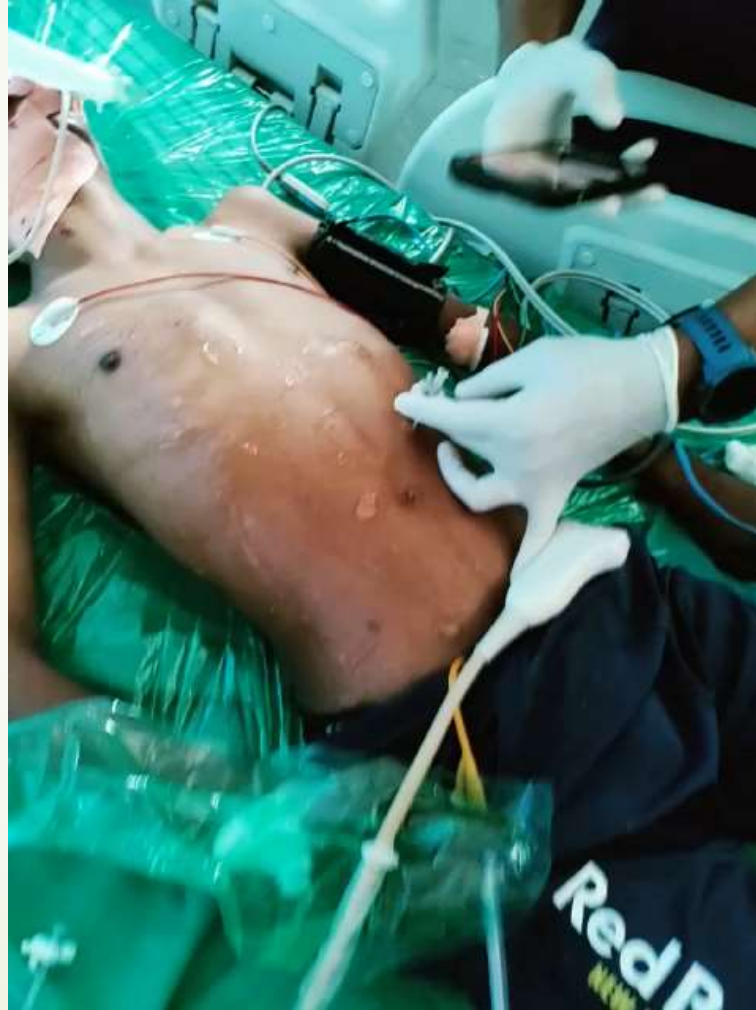


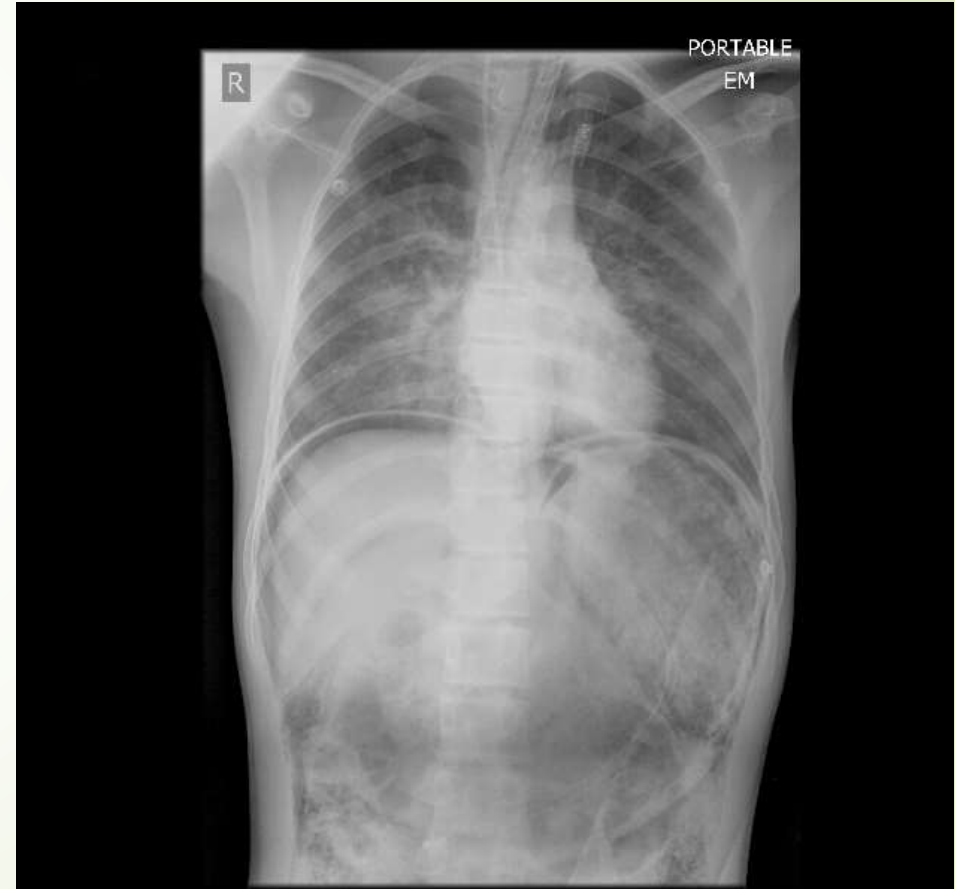
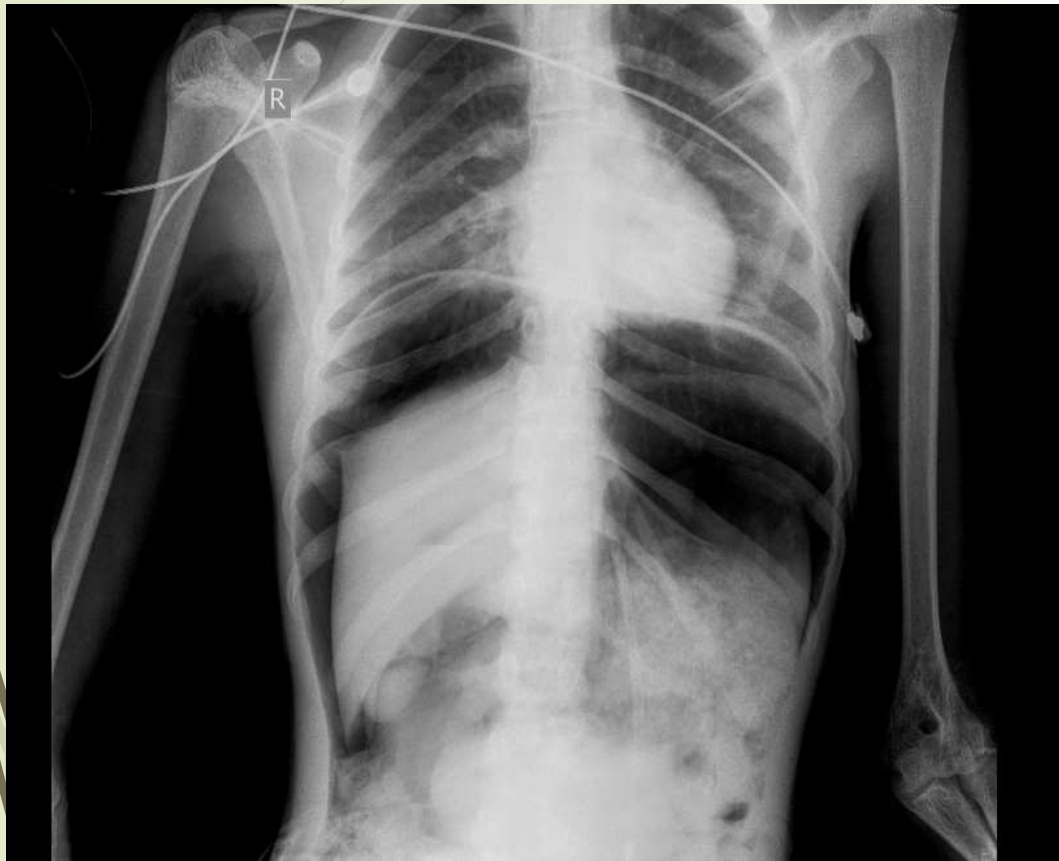

A decision to undertake Percutaneous Needle Decompression was taken.

# Percutaneous Needle Decompression









# Progress

- Immediately post procedure, patient had a recordable Blood pressure of 110/70 mmHg on dual supports.
- Patient had a waveform on pulse oximetry and a saturation of 99% on VC (100%/5/16/380)

- 
- 
- ▶ Patient was planned for surgical intervention, but had another cardiac arrest, despite thorough resuscitative measures, patient succumbed to his illness.





# DISCUSSION







# Tension Pneumoperitoneum



- Tension Pneumoperitoneum was first described in the medical literature by Oberst in 1917 when a grenade explosion resulted in gastric perforation. <sup>(1)</sup>
- Tension pneumoperitoneum is a rare disease process that few will encounter in the emergency department (ED) setting.



- 
- 
- Tension Pneumoperitonuem has since been reported as a complication of bowel perforation secondary to endoscopy, peptic ulcer disease, and bowel obstruction.



- 
- 
- It is theorized that Tension Pneumoperitoneum results from viscous perforation when overlying omental fat acts as a one-way valve, allowing gas to reach high pressures in the peritoneal cavity. (2)
  - Because the air is extraluminal, a gastric tube will not improve ventilation in these cases. (2)

- 
- 
- ▶ Although definitive management to correct the hollow viscus injury remains surgical (decompressive laparotomy), intervention by the emergency physician is warranted in the setting of unstable vital signs or prolonged delay in transfer to the operating room.

- 
- 
- As with tension pneumothorax, needle decompression can provide temporary stabilization by reducing intra-compartment pressures. (3)
  - Possible complications of percutaneous abdominal decompression include hemorrhage and bowel perforation if bowel distension and adhesion are present. (4)

- 
- 
- ▶ However, colon or organ perforation is improbable in supine patients with amounts of intra-abdominal gas large enough to cause a tension pneumoperitoneum <sup>(4)</sup>



# Take home message

- Tension Pneumoperitoneum is a very rare condition for a patient with no prior risk factors presenting to ED.
- Needle decompression before operative intervention is easy to perform, provides immediate relief, and is relatively safe when done correctly



# References

- (1) Greenish D, Pathak S, Titcomb D, Armstrong L. A rare case of tension pneumoperitoneum secondary to gastric perforation associated with severe aortic compression.
- (2) Symeonidis N, Ballas K, Pavlidis E, Psarras K, Pavlidis T, Sakantamis A. Tension pneumoperitoneum: a rare complication of upper gastrointestinal endoscopy. *JLS*. 2012 Jul-Sep;16(3):495-7
- (3) Chan SY, Kirsch CM, Jensen WA, Sherck J. Tension pneumoperitoneum. *West J Med*. Jul-Aug;165(1-2):61-4.
- (4) Chiapponi, C., Stocker, U., Körner, M. *et al.* Emergency percutaneous needle decompression for tension pneumoperitoneum. *BMC Gastroenterol* 11, 48 (2011).



Thank You