





# Beyond the Gut: A Hidden Connection

Dr Chetan Phadke  
Resident Nephrology  
DYPMCH, Pimpri



# Presentation

- 33 year old
- Female
- Chief complaints:
  - 1) Abdominal pain, infrequent loose stools since 4 months.
  - 2) Joint pains (predominantly small joints) since 2 months.
  - 3) Pedal edema and facial puffiness since 10 days.

- 
- 
- ▶ Patient was admitted in Dr D Y Patil Hospital.
  - ▶ Medical history showed no similar complaints in the past.
  - ▶ No history of:
    1. Menstrual abnormalities.
    2. Renal dysfunction.
    3. Family and siblings.
    4. Medication or known drug reactions.




► Vitals:

- Pulse: 100/ min
- BP: 122/76mmHg
- sPO2: 99% on room air

► Systemic Examination

- CVS: S1 S2 +
- RS: Air entry equal on both sides
- PA: Soft, genralised tenderness
- CNS: Conscious, alert, oriented

- 
- Hb: 11.7 gm%
  - TLC: 8400/cumm (60/29/6/5/0)
  - Platelet: 2.21lakh/ cumm
  - Urea: 18
  - Creatinine: 0.45
  - Na: 137
  - K: 3.9





➤ Urine routine:


○ Protein: 1+

○ PC: 2-3

○ RBC: 3-4

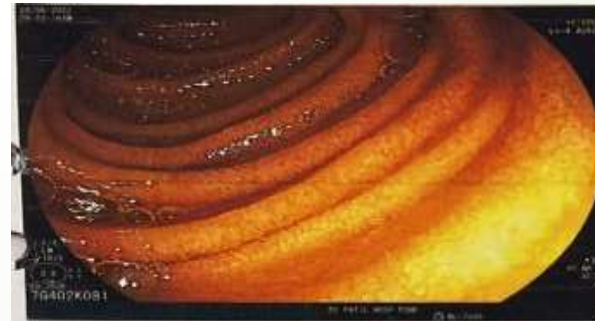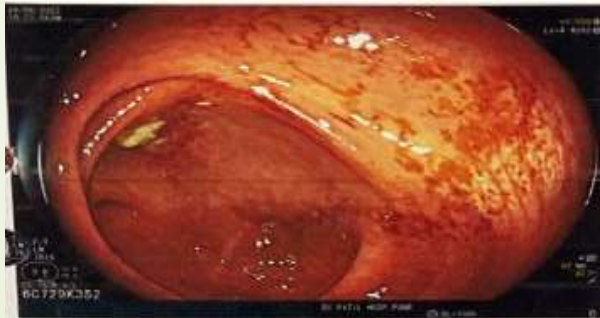➤ Nephrology consultation: Incidental proteinuria on routine evaluation.

- 
- 
- On examination, review of history and review of previous documents.
  - UPCR: 3.06 mg/mg
  - Urine culture - Sterile
  - USG: Abdomen
    - RK: 109 x 45 mm
    - LK: 105 x 45 mm
    - Bilateral increased echogenicity and maintained CMD



- 
- ▶ Patient was initiated on antibiotics in view of loose stools.
  - ▶ Patient's loose stools did not respond to routine antibiotics even after 72 hours.
  - ▶ UGI scopy and Colonoscopy planned.



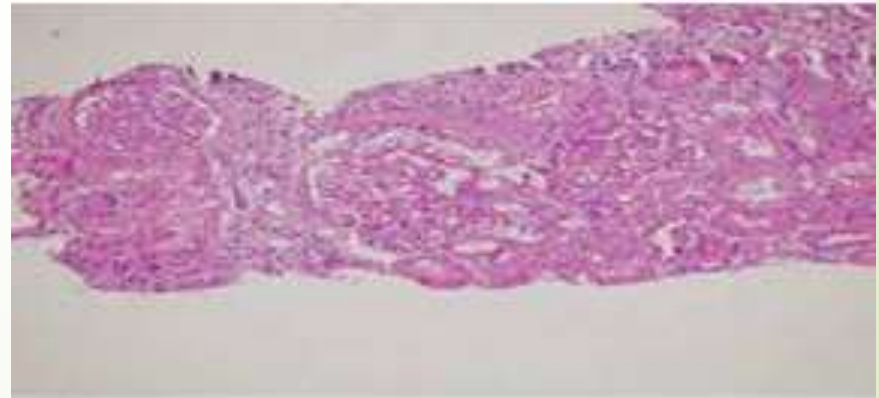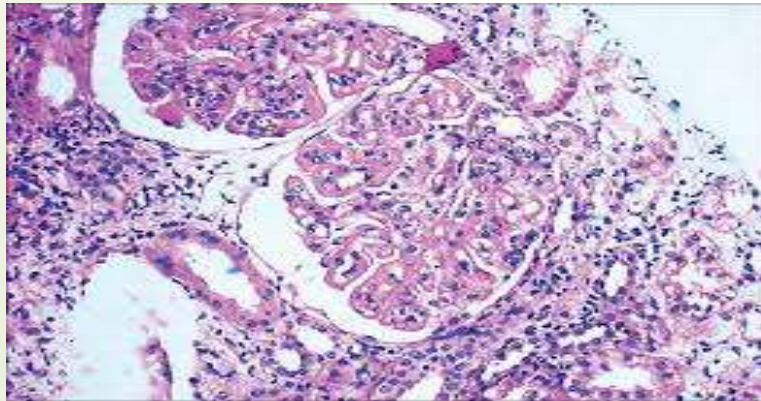
- ▶ Patient underwent UGI-scopy and Colonoscopy, report suggestive of:
  - Edema present in the oesophagus and colon
  - Biopsy: Eosinophilic infiltration in the submucosa



- ▶ Patient's autoimmune panel planned in view of UGI and colonoscopy findings.

- 
- 
- C3: 44.3 (80-110)
  - C4: 15.5 (10-40)
  
  - ANA blot
    - nRNP/ Sm: Positive
    - Sm: Positive
    - Ro 52: Positive
    - AMA M2: Positive
    - ds DNA: Positive
  
  - Urine 24hour protein: 1427 mg/ 24 hour


- ▶ Patient underwent renal biopsy without any complications.





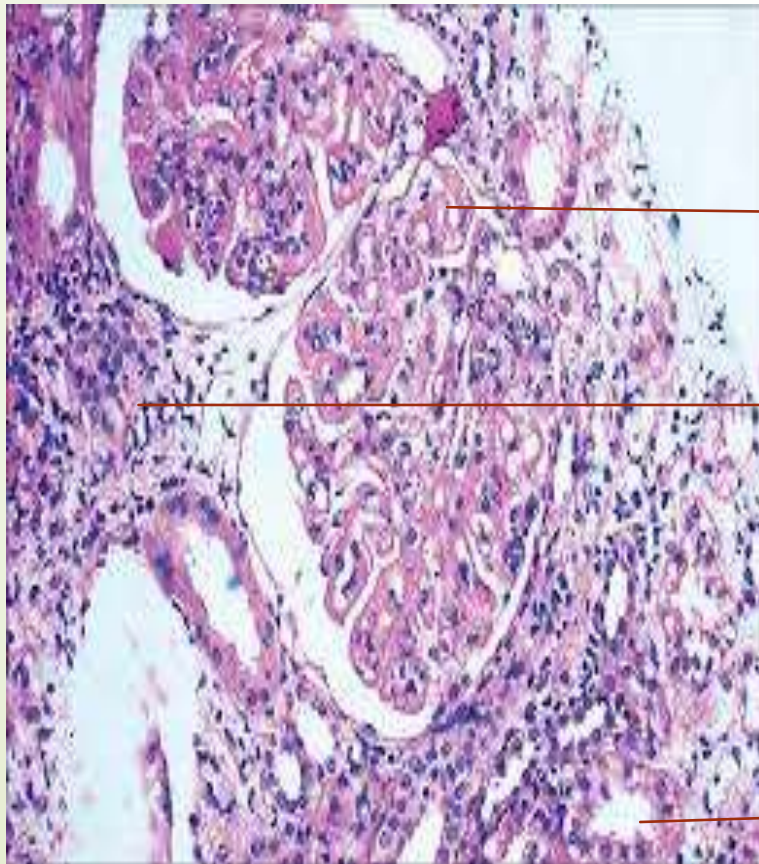
➤ Microscopy:

- 1) Glomeruli- 26 Glomeruli, 1 globally sclerosed, 8 glomeruli showing mesangial proliferation, lobulation
- 2) Tubules- Resorption droplets, diffuse tubulitis (loss of brush border and denudation in certain areas)
- 3) Interstitium- Dense mononuclear inflammatory infiltrate
- 4) Blood vessels- Unremarkable

- 
- Immunofluorescence: 3
  - IgA- 1-2+
  - IgG- 1-2+
  - IgM- 1-2+
  - C3- 2-3+
  - C1q- 1-2+





➤ **Diagnosis: Lupus Nephritis Class 3 (ISN-RPS)**



→ Glomerulus

→ Interstitium

→ Tubules

- 
- 
- ▶ Patient was initiated on Tab Prednisolone 40mg/ day and Tab HCQ-S 200 mg/ day.
  - ▶ On follow up after 2 weeks patient's symptoms responded to the steroid treatment, reduced proteinuria and no loose stools.
  - ▶ Patient followed up in Nephrology OPD 2 weeks ago in remission with no urinary or abdominal complaints and maintained on oral Prednisolone 10mg/day and HCQ-S 200 mg/ day.
  - ▶ Urine Protein- Trace, RBC absent
  - ▶ Urea 36, Creatinine of 1.01.



**SELENA GOMEZ'S BEST FRIEND GAVE HER A KIDNEY**



[WWW.LUPUSNEWSTODAY.COM](http://WWW.LUPUSNEWSTODAY.COM)







# Review


- ▶ Lupus enteritis is a rare and poorly understood cause of abdominal pain in systemic lupus erythematosus.
- ▶ Clinical symptoms: abdominal pain (97%), vomiting (42%), diarrhea (32%), fever (20%).
- ▶ Gastrointestinal symptoms: distressing,
- ▶ Renal dysfunction: dreaded complication.
- ▶ Failure to treat aggressively, eventual end stage renal disease.

- 
- 
- The kidney is the most commonly involved visceral organ in SLE.
  - Although approximately 38% of patients may have renal dysfunction of some sort at presentation.
  - With improved diagnostic and treatment modalities, death due to lupus nephritis has reduced.

- Manifestations of Systemic Lupus Erythematosus; [Maedica \(Bucur\)](#). 2011 Oct; 6(4): 330–336.


- 
- 
- ▶ Timely diagnosis remains of the essence.
  - ▶ SLE: leading causes of death in young women in the U.S. (2000 and 2015).
  - ▶ In women ages 15–24 years, SLE was the number one cause of death among chronic inflammatory diseases, ranking higher than diabetes mellitus

- SLE mortality remains disproportionately high, despite improvements over the last decade; [Lupus 2018 Sep; 27\(10\): 1577–1581](#); 2018 Jul 17

- 
- The lifetime incidence of lupus nephritis in SLE patients remains 100%.
  - All patients should undergo kidney biopsy: slightest renal involvement
  - Biopsy at diagnosis helps to classify the disease
  - Serves as baseline for future reference.
  - Prompt treatment helps preserve renal function.



# Discussion

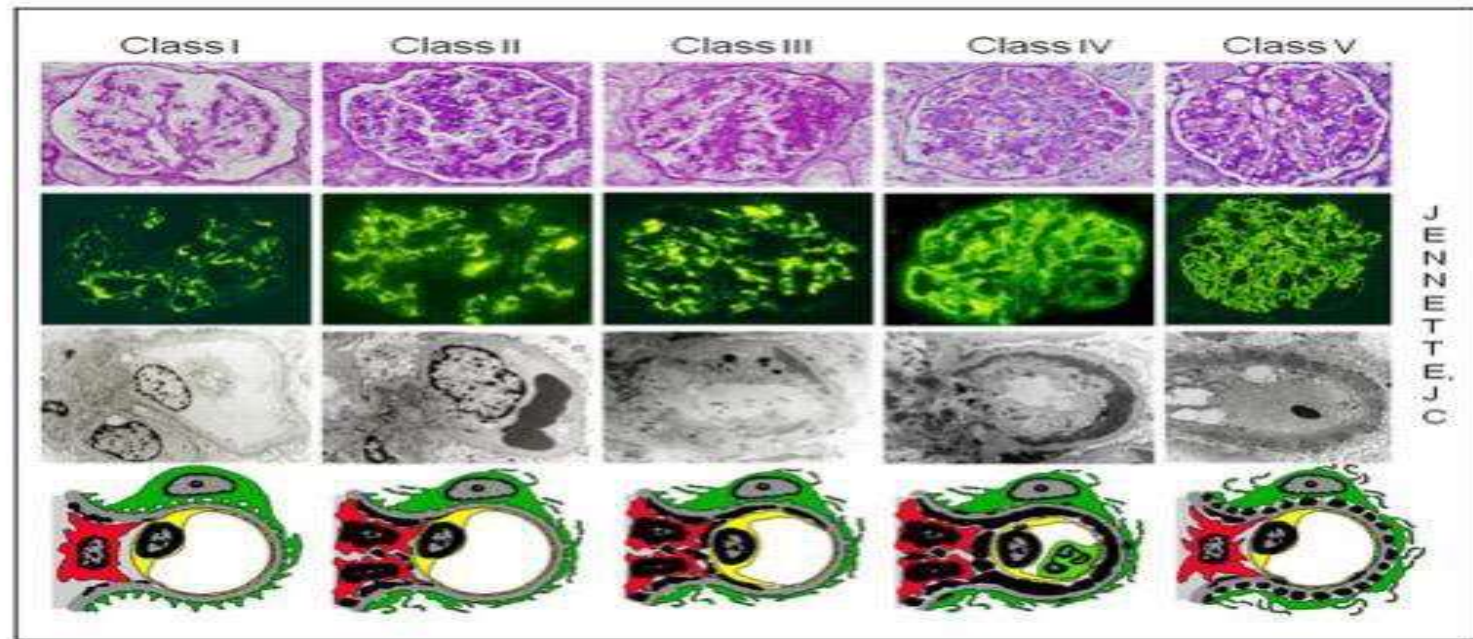
- SLE: Multi-organ disease
  - Serious complications: End stage organ failure, death.
  - Atypical presentations often pose a diagnostic dilemma
  - May delay diagnosis and treatment.
- 





**Table 1: The 2003 International Society of Nephrology and International Pathology Society Classification of lupus nephritis**

- Class I: Minimal mesangial lupus glomerulonephritis (LGN)
- Class II: Mesangial proliferative LGN
- Class III: Focal LGN (< 50% glomeruli)
- Class IV: Diffuse LGN ( $\geq$  50% glomeruli)
  - Class IV-S: Predominantly segmental
  - Class IV-G: Predominantly global
- Class V: Membranous LGN

Class VI: Advanced sclerotic LGN (> 90% sclerotic glomeruli)



- 
- 
- ▶ Early diagnosis and treatment: long, relatively normal life.
  - ▶ Diagnostic guidelines help in the diagnosis of atypical presentations.
  
  - ▶ We put forth this case to bring attention of clinicians to the possible variations and variety of this disease and to bear in mind the diagnosis of SLE in patients.



Thank You

