



AN INTERESTING CASE OF ENCEPHALOPATHY


DEPARTMENT OF GENERAL MEDICINE

CASE STUDY

- 27 year male , who was working in construction site {in the month of **APRIL, 2023**} had presented with :
- **H/o strenuous activity near construction site under hot atmosphere for the past 5 days**
- With sudden onset of giddiness, altered sensorium for 4-5 hours associated with irrelevant talk which progressed to blurring of vision and loss of consciousness, High grade fever (**106 degree F**) ,Hypotension (**BP: 80/40 mm hg**) , Tachycardia ,

- H/o Focal seizures 1 episode and was admitted in outside hospital for 5days with labs suggestive of **thrombocytopenia** and **deranged LFT'S** and **RFTs**.
- The patient was treated with **Vasopressor support** and **IVF challenge**.

Patient presented to DR. D. Y. PATIL HOSPITAL with the complaints of :

- High grade fever
 - Altered sensorium
 - Bilateral UL and LL weakness.
- 
- For the past 5 days
- No h/o fall/trauma
 - No h/o of urinary & bowel incontinence/ up rolling of eyes/ frothing from mouth/ tongue bite
 - No h/o medication intake.

Past History

- No h/o any co-morbidity
- No h/o any surgery
- No h/o any blood transfusion/drug history

PERSONAL HISTORY

- Vegetarian diet
- No Addictions
- Sleep, Appetite are normal
- Bowel and Bladder habits are unaltered

Family History

- No h/o any relevant disease in family.

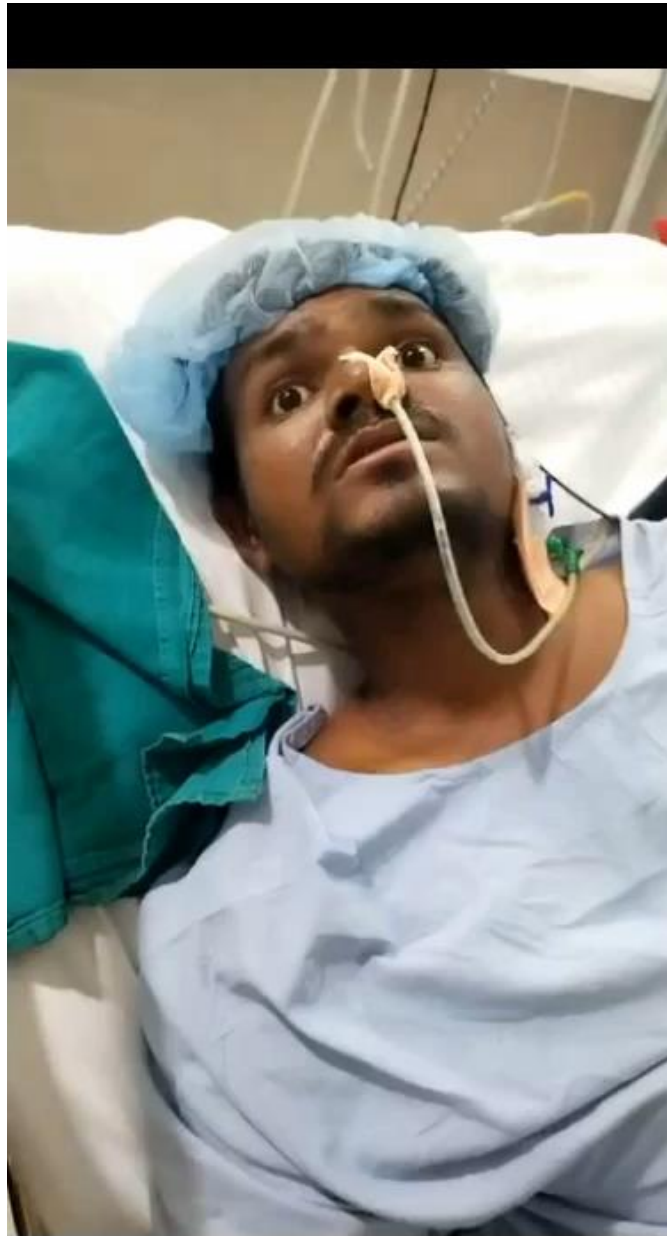GENERAL EXAMINATION

On Examination :

Patient was febrile; core body temperature was 104 degree F .

- PR : 120 bpm
- BP : 100/60mmHg
- RR : 22/min
- Spo2 : 97% on room air

- NO Pallor/Icterus/clubbing/cyanosis/ lymphadenopathy/oedema/rash
- BSL Random – 90 mg/dl
- Urine Output – 800 ml/day



CNS EXAMINATION

HIGHER MENTAL FUNCTIONS :

- Patient is disoriented to time , place , person.
- GCS : E4 V2 M1
- No meningeal sign

Motor Function :

- Tone: Hypotonia
- Power : 0/5 in B/L upper limbs and lower limbs
- Reflexes : Areflexia
- B/L Plantars : mute
- Involuntary movements of face and eyes.
- Left upper limb focal seizures present.

OTHER SYSTEMS : Normal

WORKING DIAGNOSIS?

1. Dengue Fever
2. Heatstroke
3. Cerebrovascular accident
4. Meningitis
5. Encephalitis
6. Malignant Hyperthermia
7. Hypothalamic bleeding / Infract

INVESTIGATIONS

INVESTIGATION	VALUE	INVESTIGATION	VALUE	INVESTIGATIONS	VALUES
Hemoglobin	10.5	Na/K/Cl	136/4.15/101	CRP	41
TLC	8000	S. Ca/PO4/Mg	8.4/3.7/2.5	ESR	19
Platelet count	46,000	D dimer	1008	S . Procal	0.2
Bilirubin T/D	3.95/2.08	Fibrinogen	180	Dengue/widal/ Malaria	Negative
AST/ALT/ALP	81/94/ 140	CPK-NAC	324	CSF Routine & c/s	Negative
HIV/HbSAg/HCV	Non Reactive	PT/INR	11.1/1.2		
Urea	20	Urine r/m	WNL		
Creatinine	1.6	Blood/urine culture	Negative		

- Fundus examination: Normal
- **USG Abdomen : Mild hepatomegaly (17cm)**
- Chest X-ray , ECG normal ,2D Echo – Normal.
- MRI BRAIN & MRI WSS : Normal on Day 1 and 8
- **NCV suggest : Axonal sensory motor neuropathy involving LL >UL**

- Furthermore, Patient neurological status was not improved



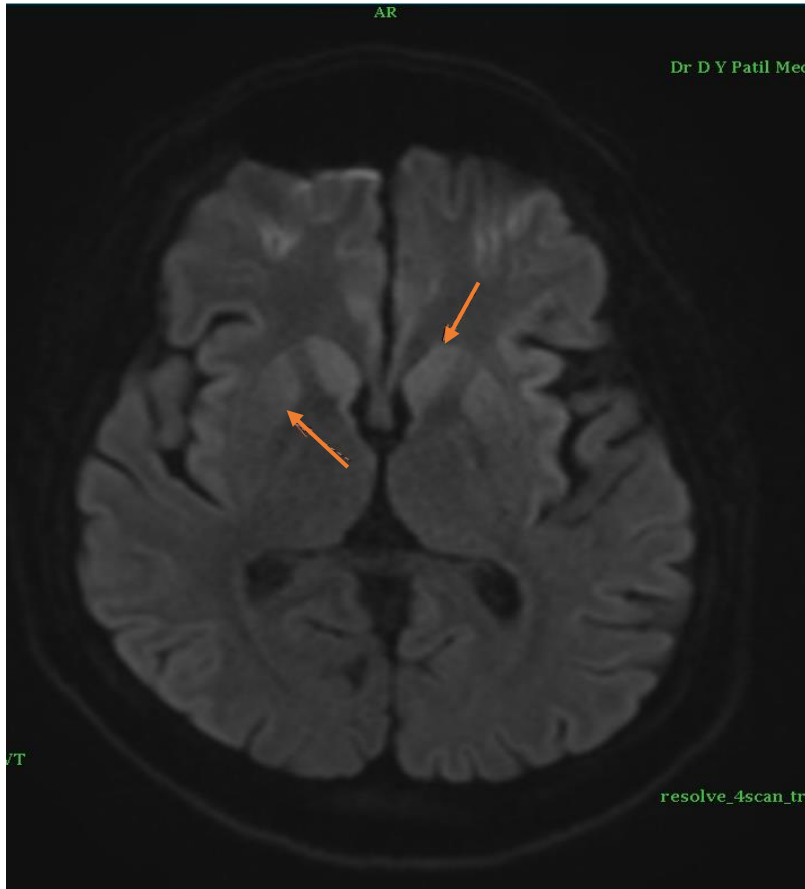
MRI BRAIN & WSS repeated on Day 15

- **MRI WHOLE SPINE SCREENING** showed straightening of cervical spine likely due to Paraspinal muscle spasm
- **EEG** suggestive of generalized background 5-6 Hz suggestive of **Diffuse Encephalopathy**.

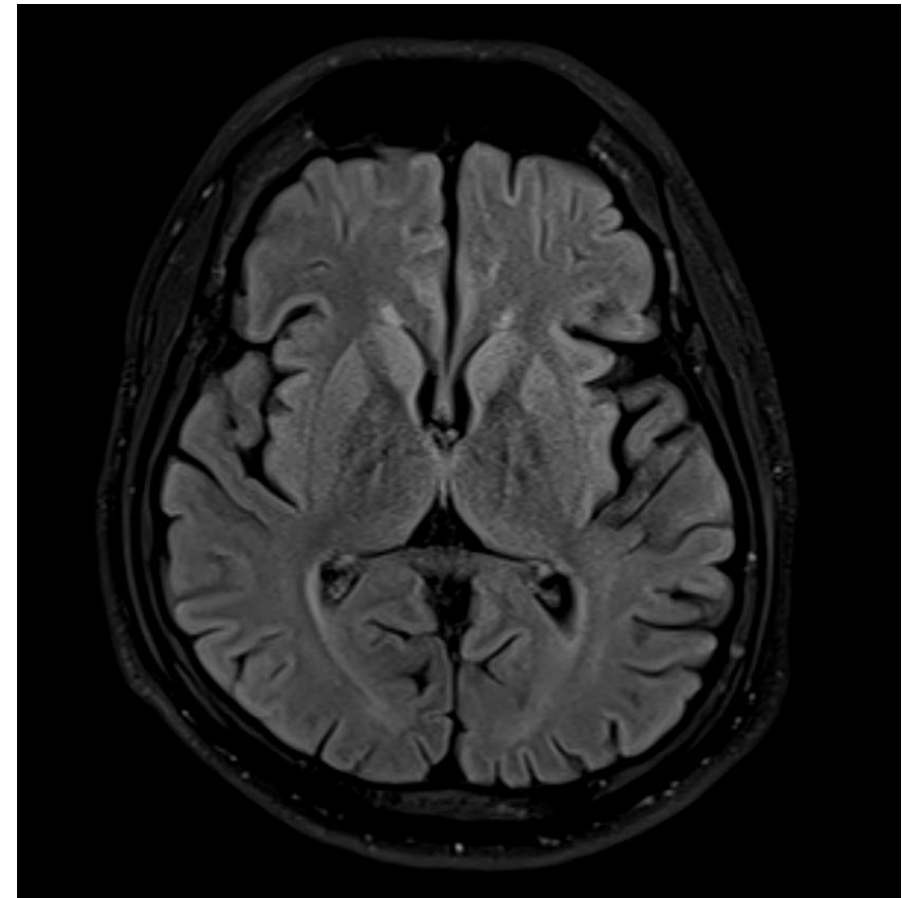
- **CSF studies repeated on day 15**
- **CSF routine and c/s – Normal**

Sent :

1. **CSF Pan – Neurotropic viral Panel**
 2. **CSF HSV- PCR Panel**
 3. **CSF Rickettsial panel**
 4. **Autoimmune encephalitis panel**
- **RESULT : Negative**



DIFFUSE WEIGHTED IMAGING



FLAIR

MRI BRAIN : Subtle symmetrical areas of restricted diffusion with hyperintensities on FLAIR involving **Bilateral caudate nuclei ,anterior aspect of bilateral putamen and bilateral insular cortex , suggestive of Infective/metabolic Encephalopathy.**

DIFFERENTIAL DIAGNOSIS

Taking MRI as consideration it could be:

- 1) Metabolic/Infective/Autoimmune Encephalopathy
- 2) Exertional Heatstroke Encephalopathy
- 3) Acute inflammatory demyelinating polyneuropathy

TREATMENT

- Temperature was monitored.
- IV FLUIDS , cold sponging and IV antibiotic given
- Inj. Levetiracetam 1gm , Anti-viral I.V Acyclovir 800 mg tds was given empirically.

As pt neurological status didn't improve



He has been treated with pulse therapy IV Methylprednisolone {1gm /day} od × 5 days

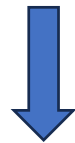

F/b Intravenous Immunoglobulin trial of {2gms/kg } given × 5 days with supportive management.

At subsequent time, pt showed minor neurological improvement but with persistent **quadriparesis muscle power 1/5, Oro-mandibular dyskinesia and dysphagia.**

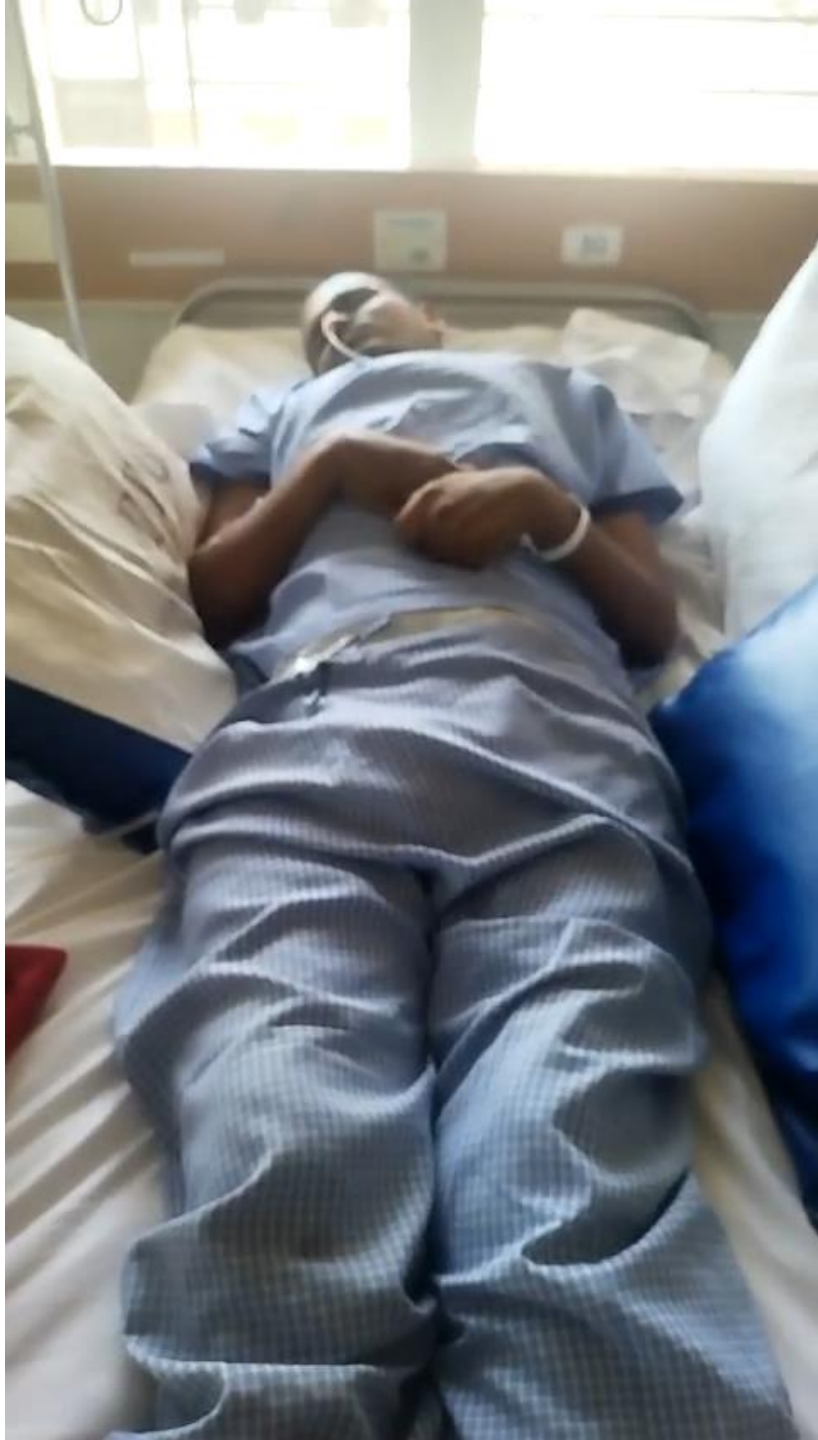

Patient was given supportive management and Physiotherapy for 1month in the ward .



On discharge, patient was able to obey commands , unable to sit or stand on his own. {muscle power :2/5}

On follow up :Patient is continuing Physiotherapy , able to do his daily routine activity , & walks with support .



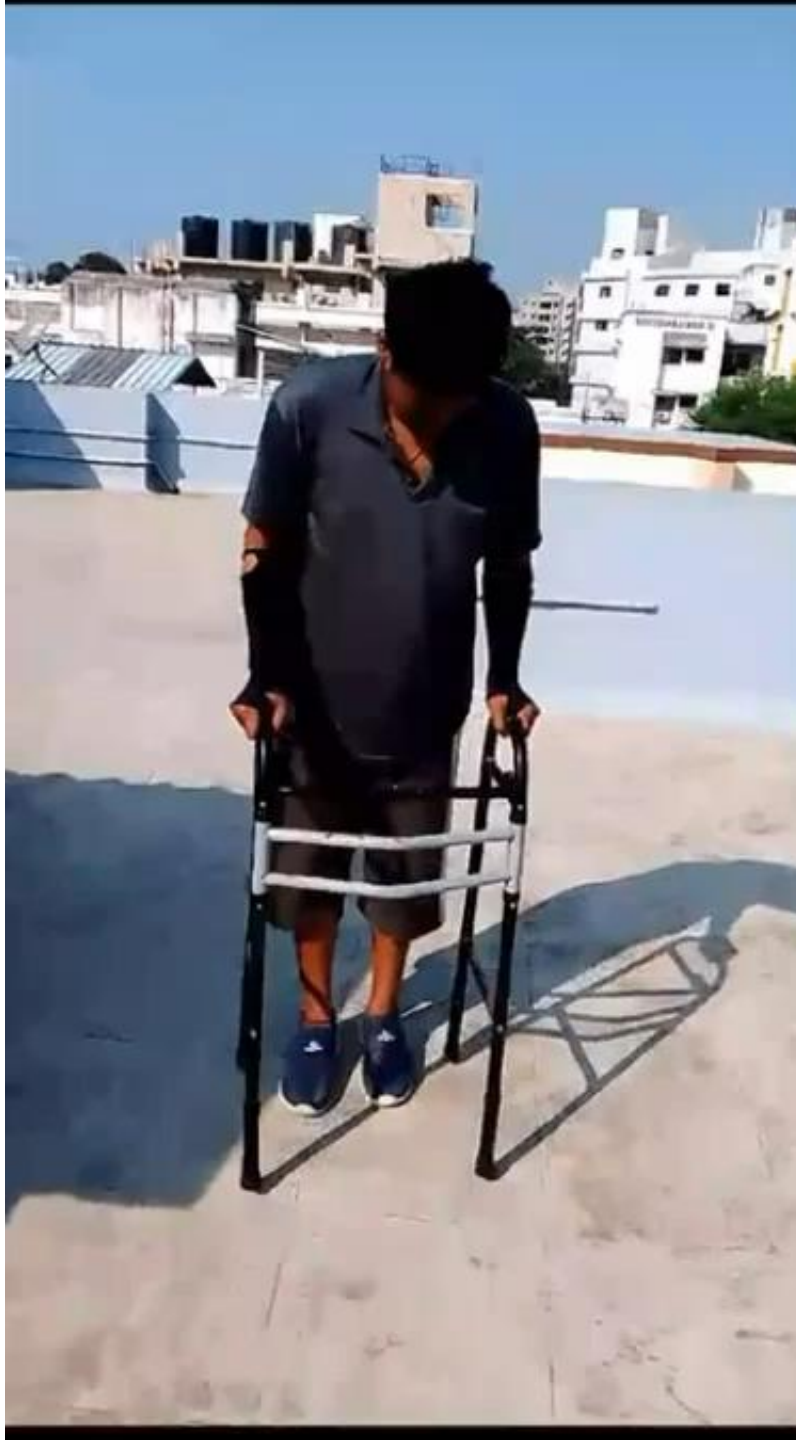Patient obeying
command

FINAL DIAGNOSIS

Based on History , Clinical Presentation , Lab Reports , MRI brain this case has been diagnosed as



EXERTIONAL HEATSTROKE
ENCEPHALOPATHY



Current status of
the patient

DISCUSSION

- In **Heatstroke Encephalopathy** the **Core body temperature ≥ 40 to 40.5 degree C** accompanied by CNS dysfunction.
- It represents a failure of body's ability to maintain thermoregulation.
- **Typical vital signs** : Tachycardia , Tachypnea, Hypotension , widened pulse pressure.
- The triad of exposure to a heat stress, and core temperature > 40.5 degree C ,CNS dysfunction, helps in preliminary diagnosis.

PATHOPHYSIOLOGY

The pathophysiological mechanism of CNS damage is believed to be multifactorial

Due to direct thermal injury there will be destruction of cerebellar Purkinje cells



Leading to alterations in brain perfusion, vasodilation, causing brain oedema and subsequent vasoconstriction secondary to hypovolemia, causing microvascular alterations and ischemic changes



SHWARTZMAN REACTION.

- Renal failure can occur from direct thermal injury, leading to :
 - Rhabdomyolysis
 - Volume depletion.

If patients mental status does not improve with cooling



Toxicologic screening , Cranial CT, Spinal fluid analysis can be considered.

- Treatment includes cooling strategies like **Evaporative cooling** and **Immersion cooling**.
- The **True incidence** of Heat Stroke is unknown because of frequent **misdiagnosis**.

TAKE HOME MESSAGE



In our case **MRI may not be a sensitive indicator** in early phase of heatstroke and heatstroke can cause neuro deficit that may persist.



And high degree of clinical suspicion for “**Heatstroke encephalopathy**” should be considered if the patient didn’t improve neurologically as expected.



The interest of our case lies in the rarity of the **clinical presentation** & **presence of the classic lesions in the caudate nuclei.**

References

1. Gaudio FG, Grissom CK. Cooling methods in heat stroke. *J Emerg Med.* 2016;50:607–16.
2. Albukrek D, Bakon M, Moran DS, Faibel M, Epstein Y. Heat-stroke-induced cerebellar atrophy: clinical course, CT and MRI findings. *Neuroradiology.* 1997;39:195–197. doi: 10.1007/s002340050392. [[PubMed](#)] [[CrossRef](#)] [[Google Scholar](#)]
3. Sudhakar PJ, Al-Hashimi H. Bilateral hippocampal hyperintensities: a new finding in MR imaging of heat stroke. *Pediatr Radiol.* 2007;37:1289e91. [[PubMed](#)] [[Google Scholar](#)]

THANK YOU