

A Case of Advanced Keratoplasty



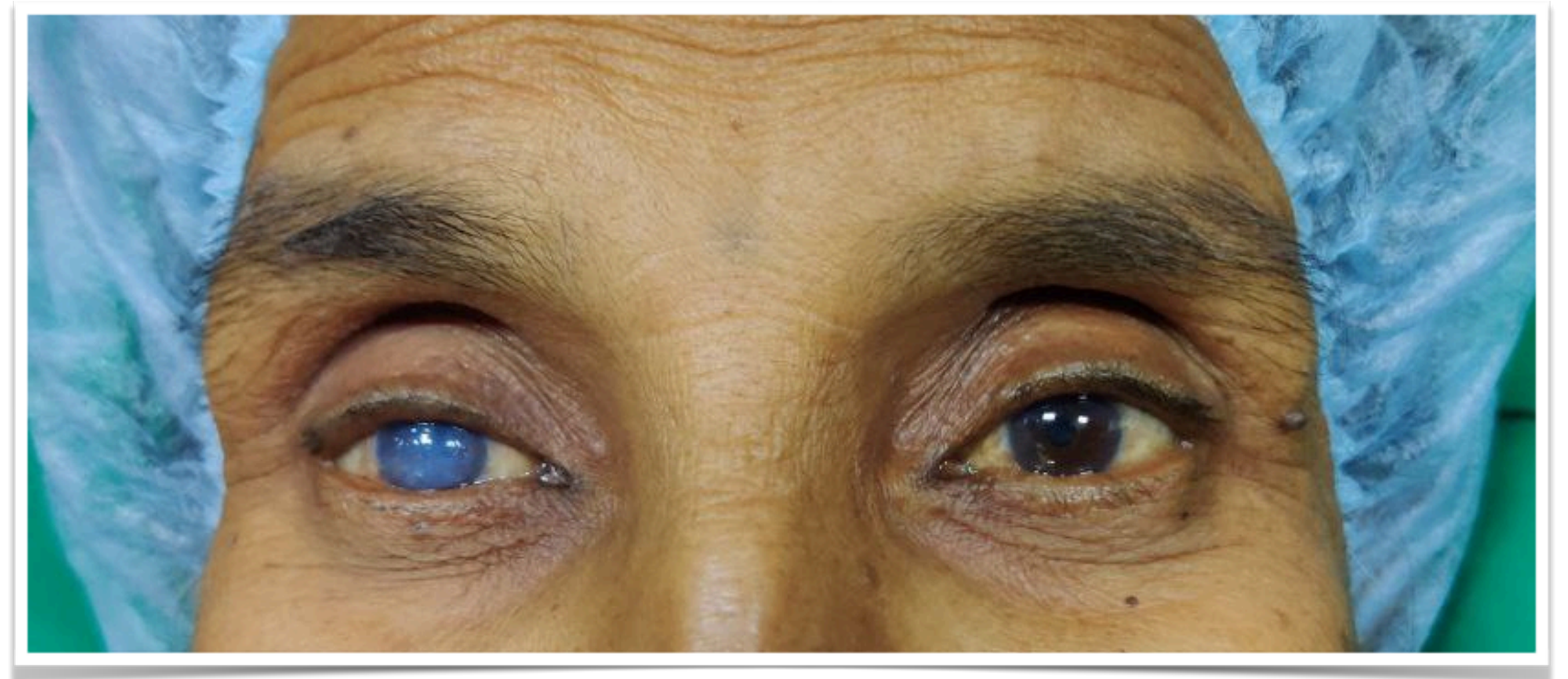
Dr. Apeksha

COMPLAINTS

- A 60 year old female came to the ophthalmology OPD with complaints of diminution of vision in RE associated with pain and redness since 2 years, following cataract surgery.

HISTORY OF PRESENTING ILLNESS

- Diminution of vision was in the RE 2 months following cataract surgery which was gradual in onset, progressive and painful in nature
- Pain was dull aching type, and continuous in nature and was associated with redness in the same eye
- There were no aggravating or relieving factors

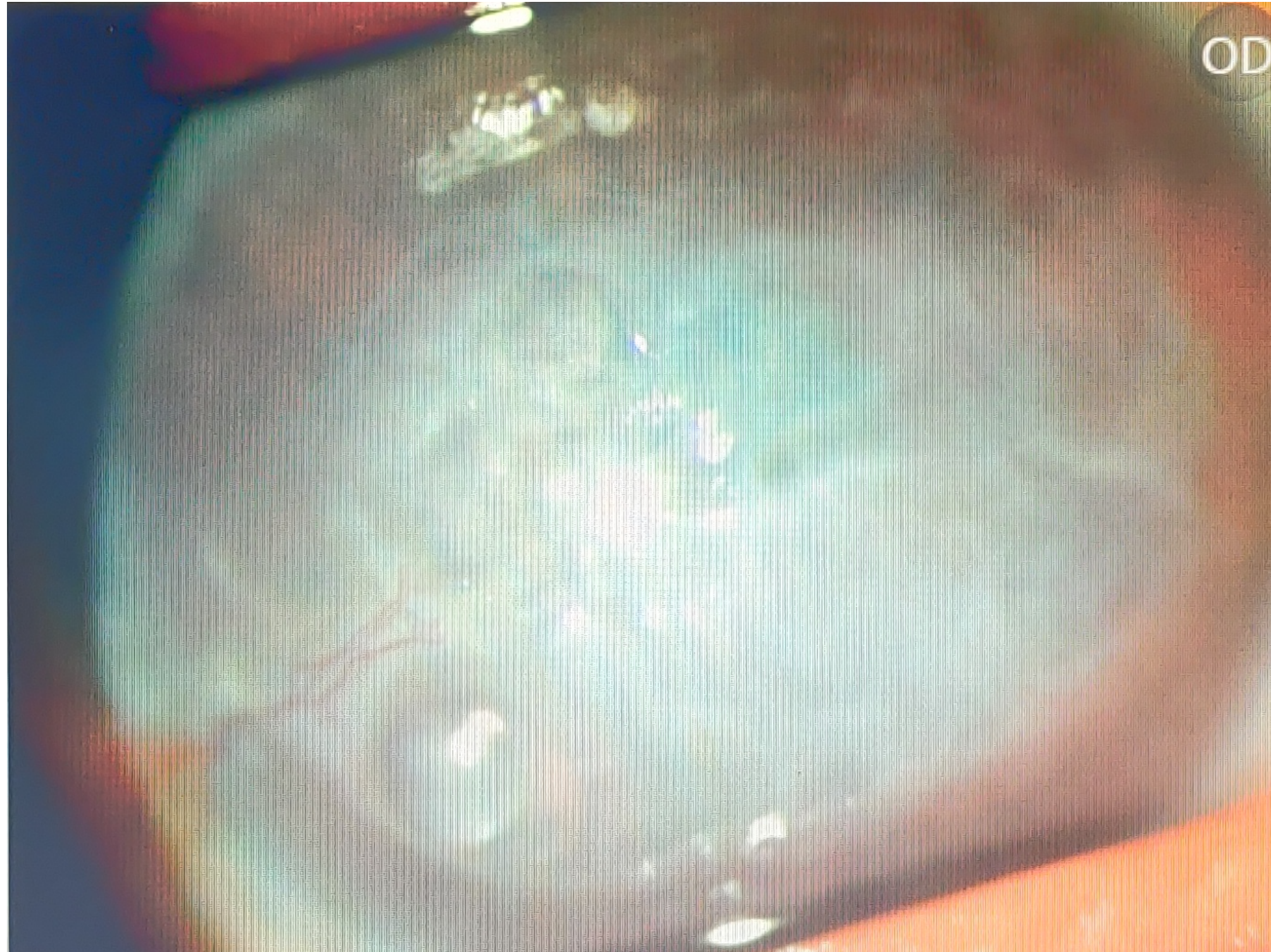


OCULAR EXAMINATION

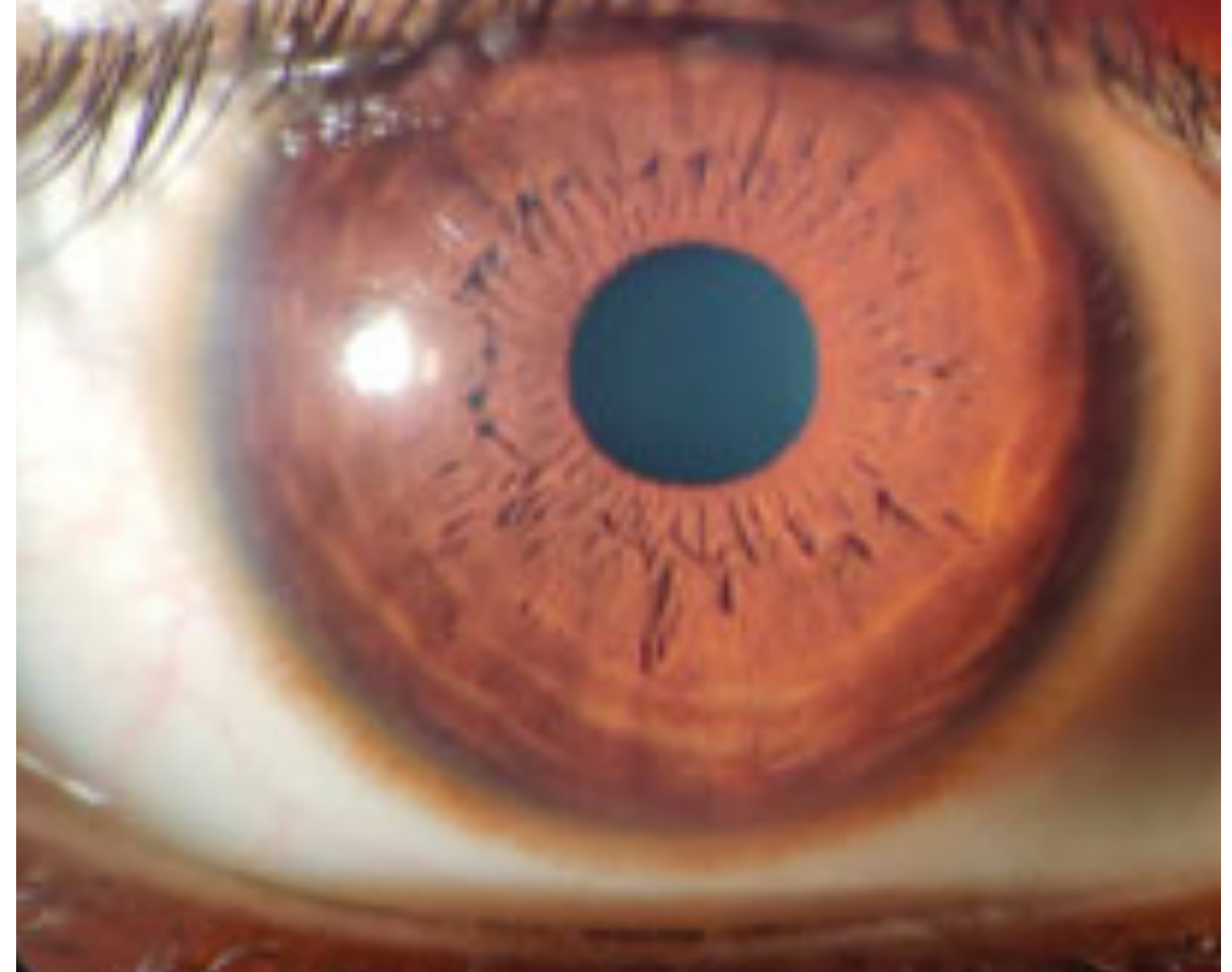
	RE	LE
VISION	Hand movements, Projection of rays accurate in all quadrants —> Not improving	6/18 —> 6/9
Best Corrected Visual Acuity (BCVA)	Not improving	-0.75 DS
EXTRAOCULAR MOVEMENTS	Full, free, painless	Full, free, painless
HEAD POSTURE	Central	
ORBITAL MARGINS/ EYEBROWS/ EYELIDS	Normal	

CORNEA

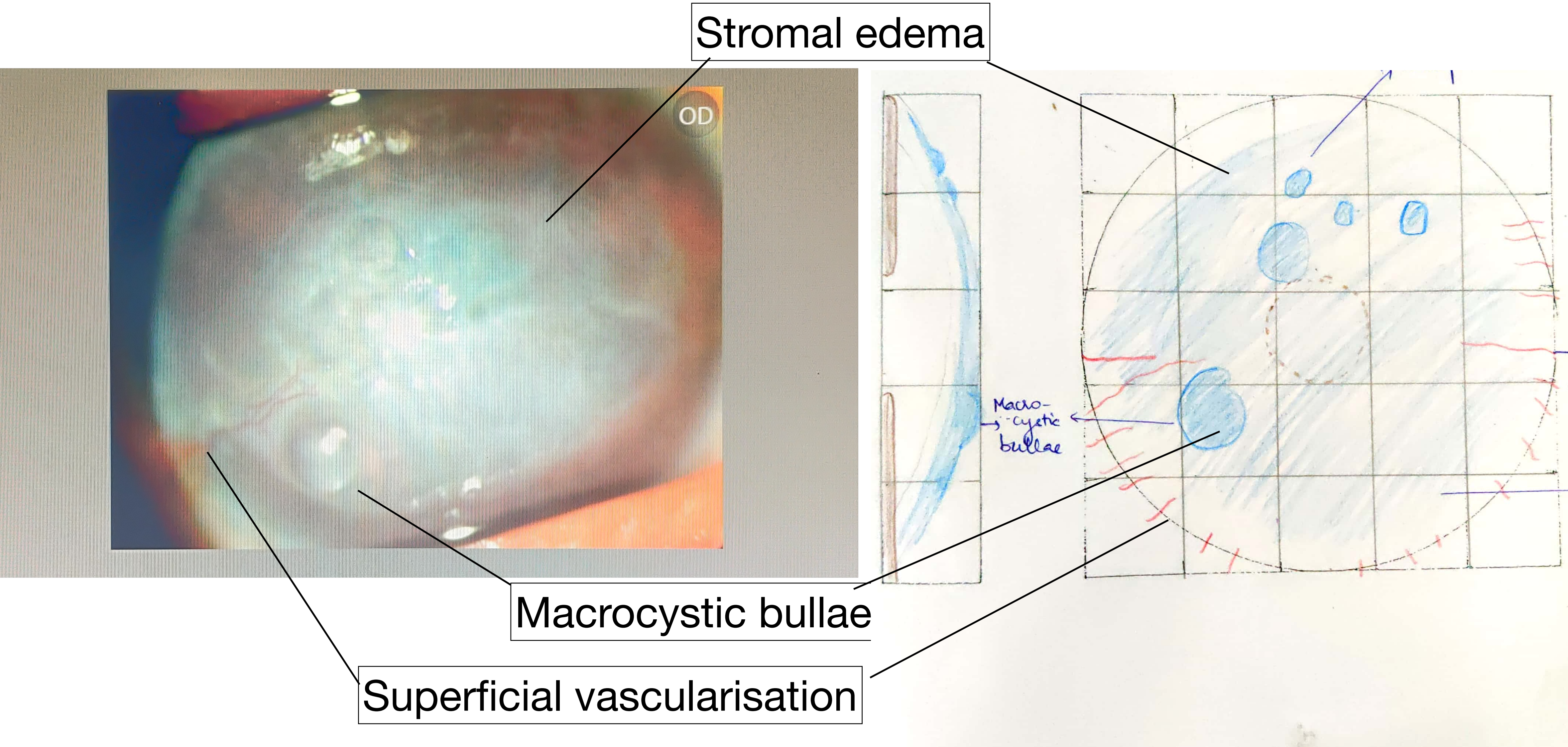
RIGHT EYE



NORMAL EYE



ANTERIOR SEGMENT EXAMINATION OF RIGHT EYE



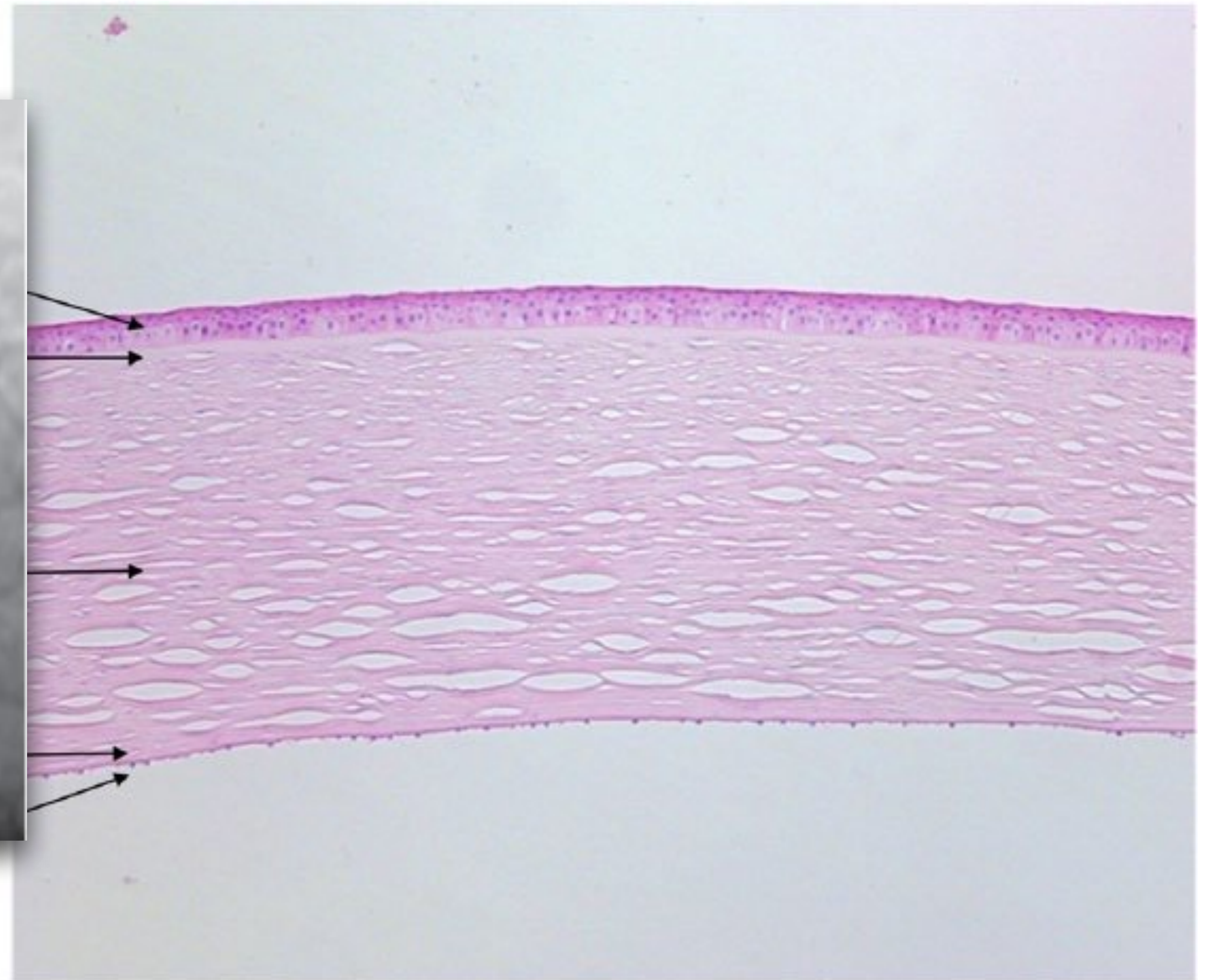
PROVISIONAL DIAGNOSIS

RE PSEUDOPHAKIC BULLOUS KERATOPATHY
LE IMMATURE SENILE CATARACT

Structure of the Cornea



Endothelium



PLAN OF MANAGEMENT:

CORNEAL TRANSPLANT

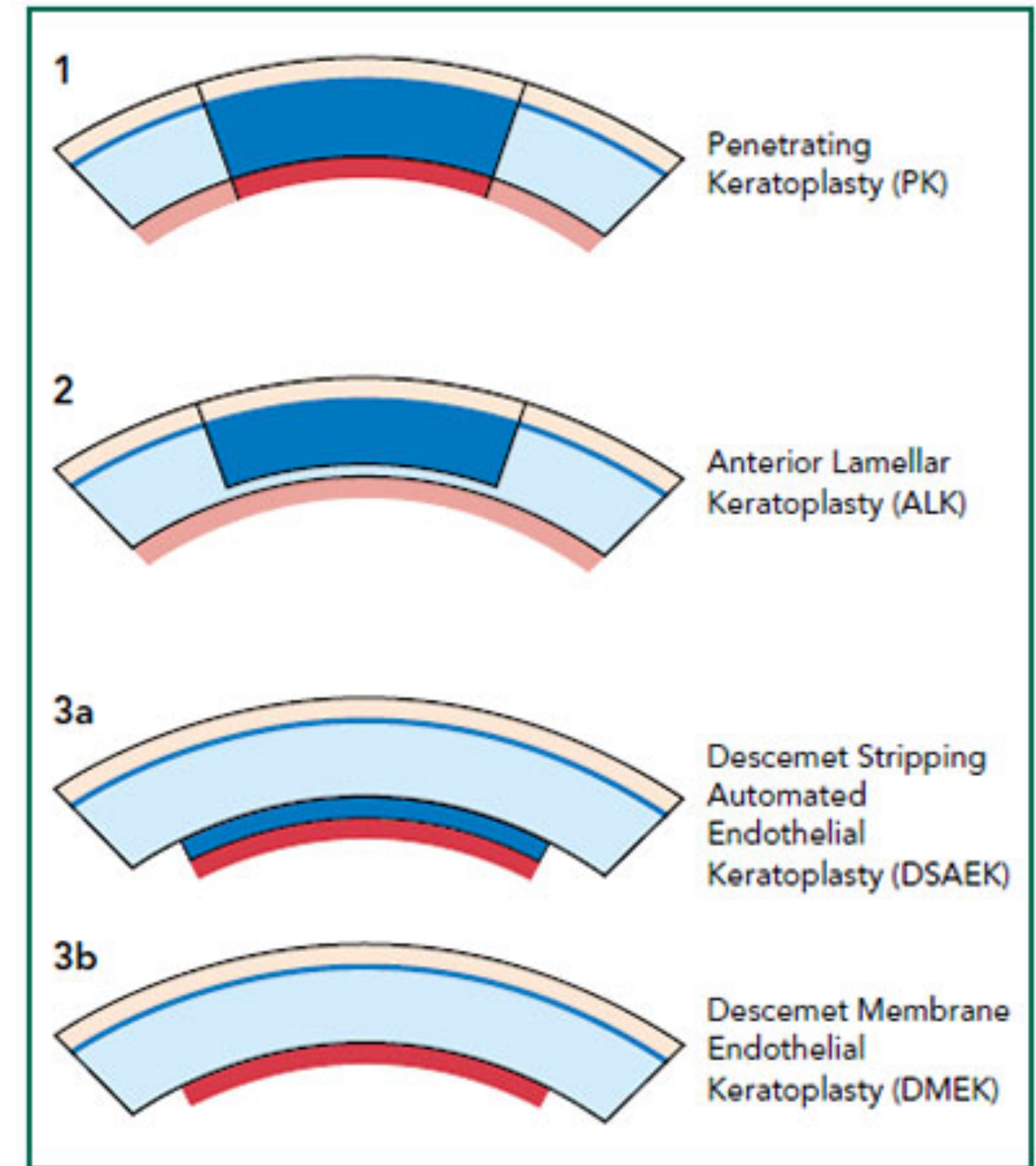
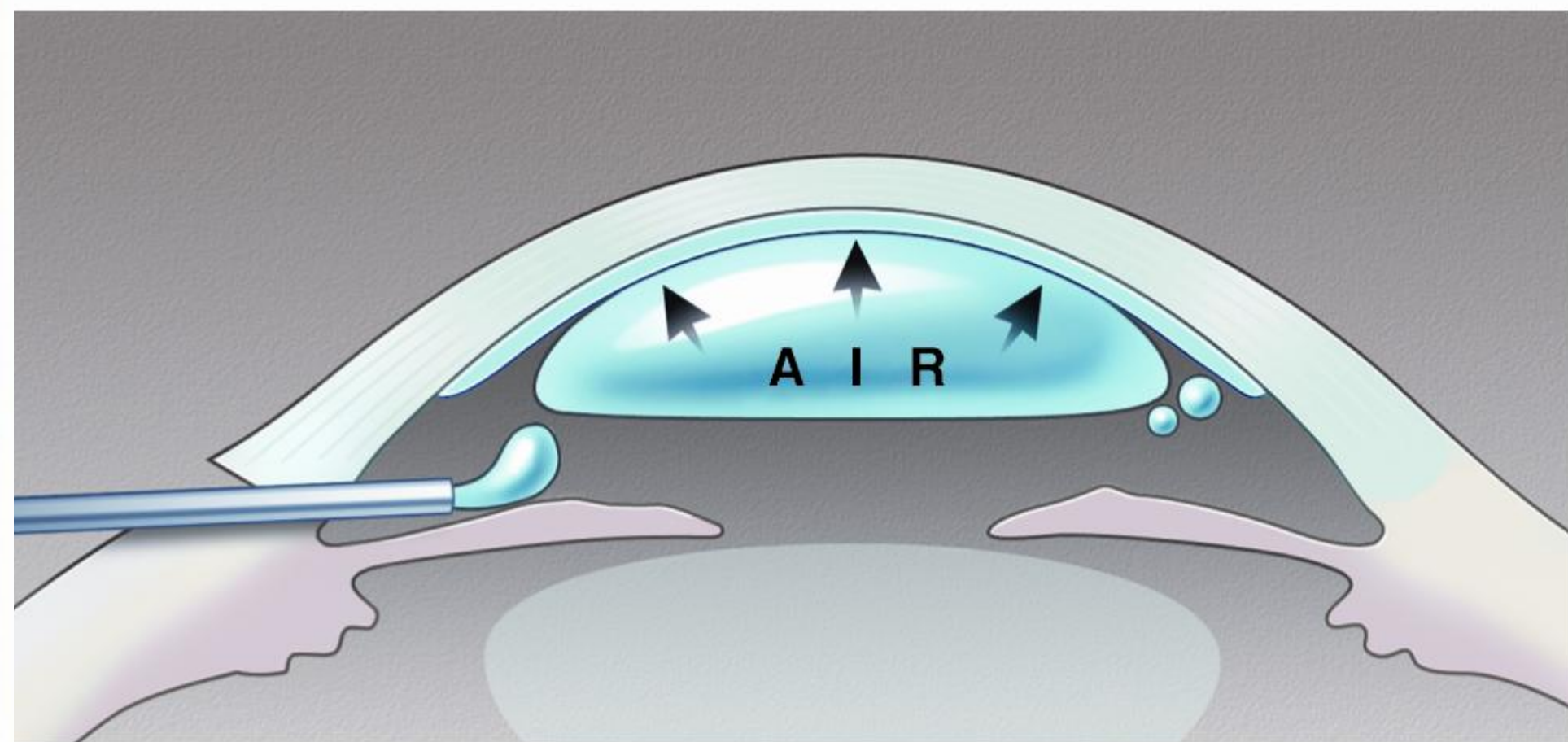
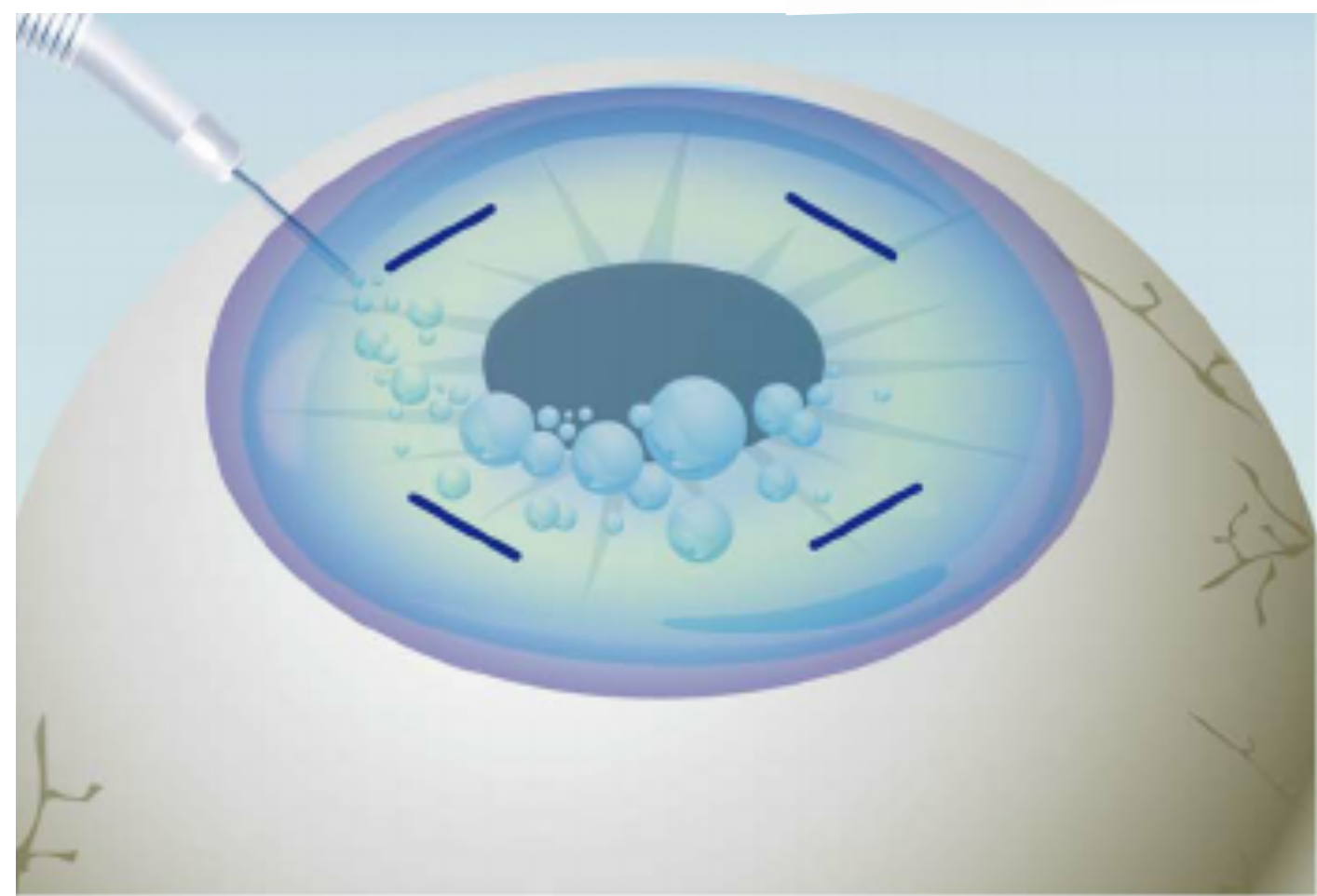
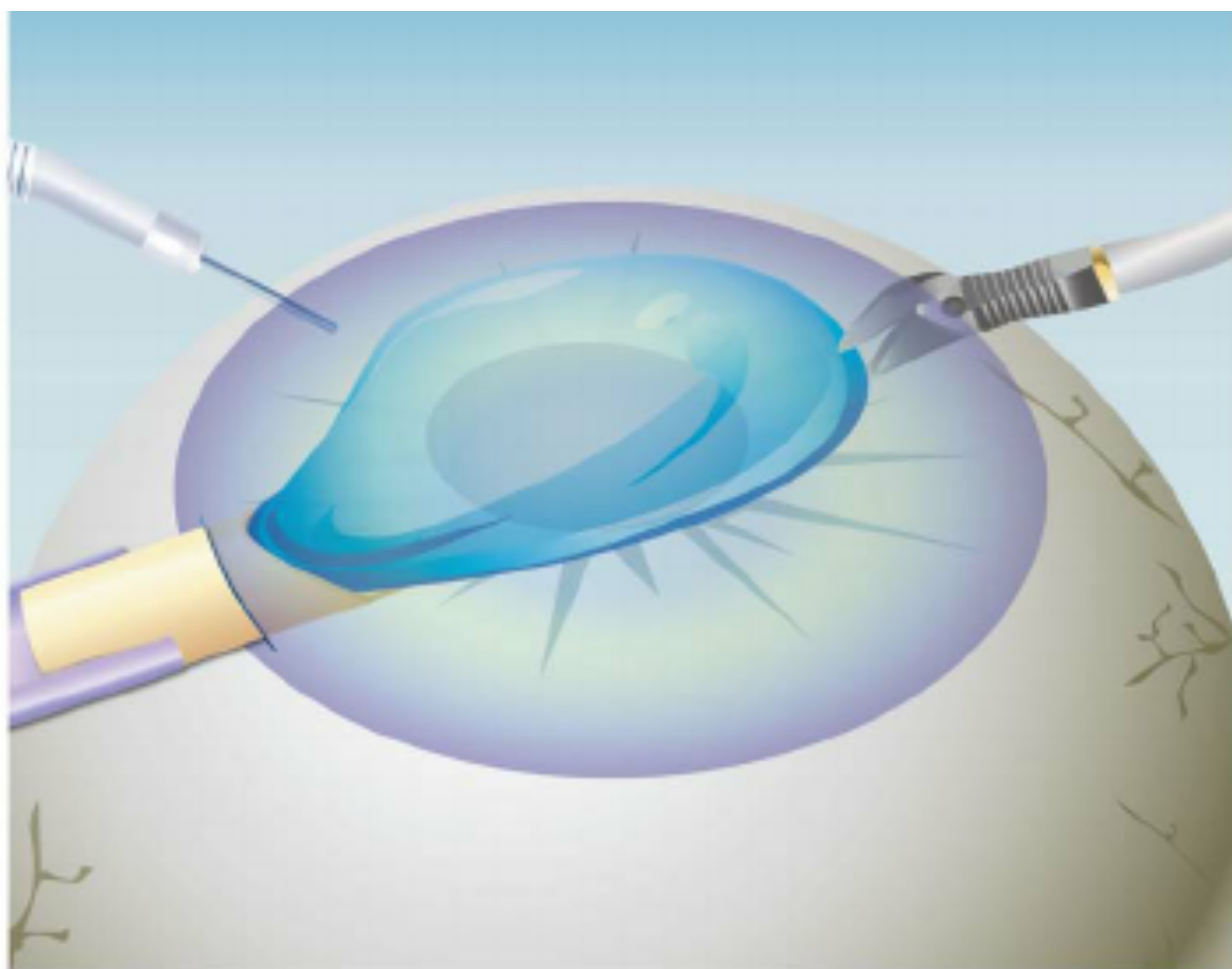
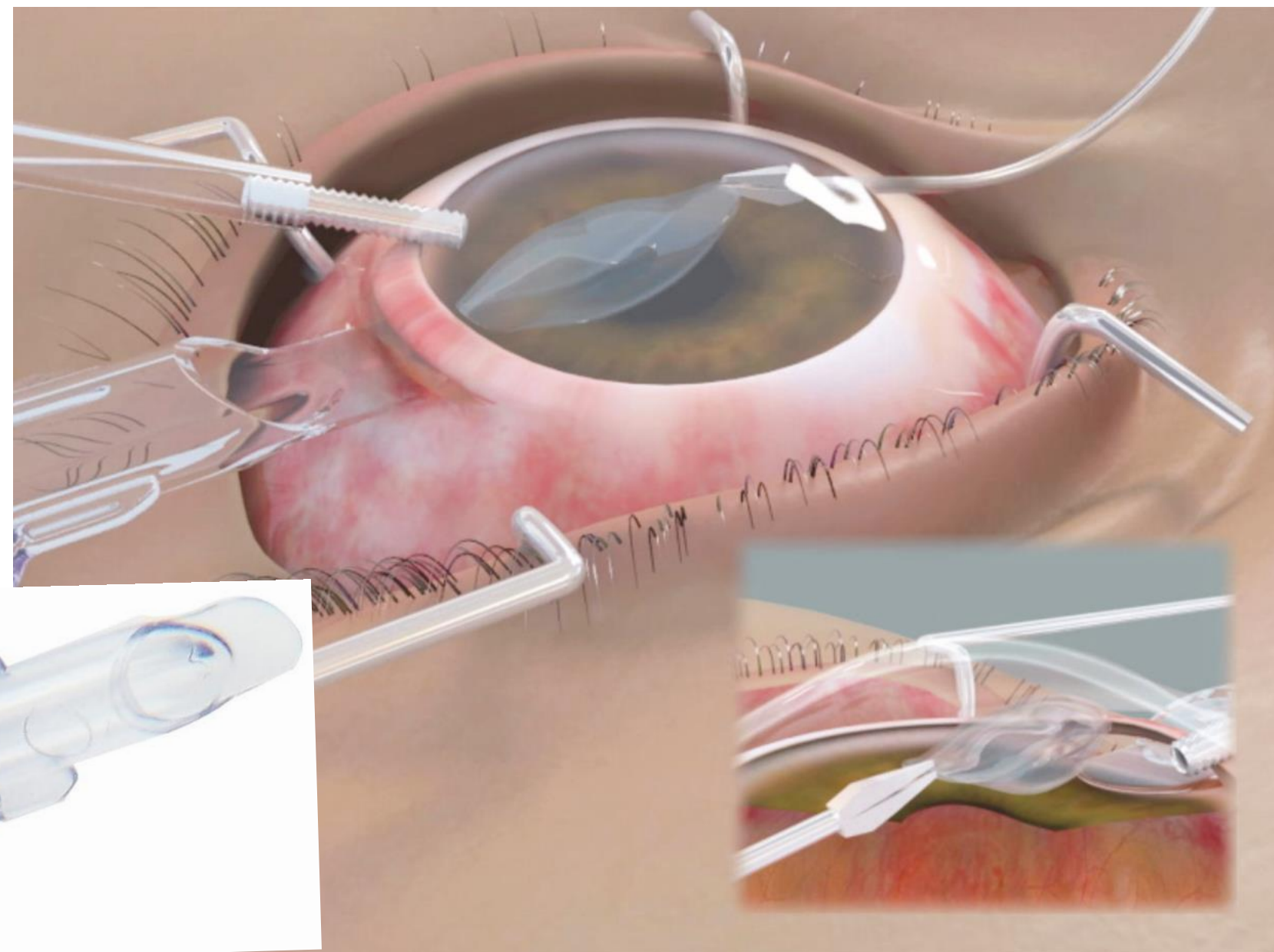
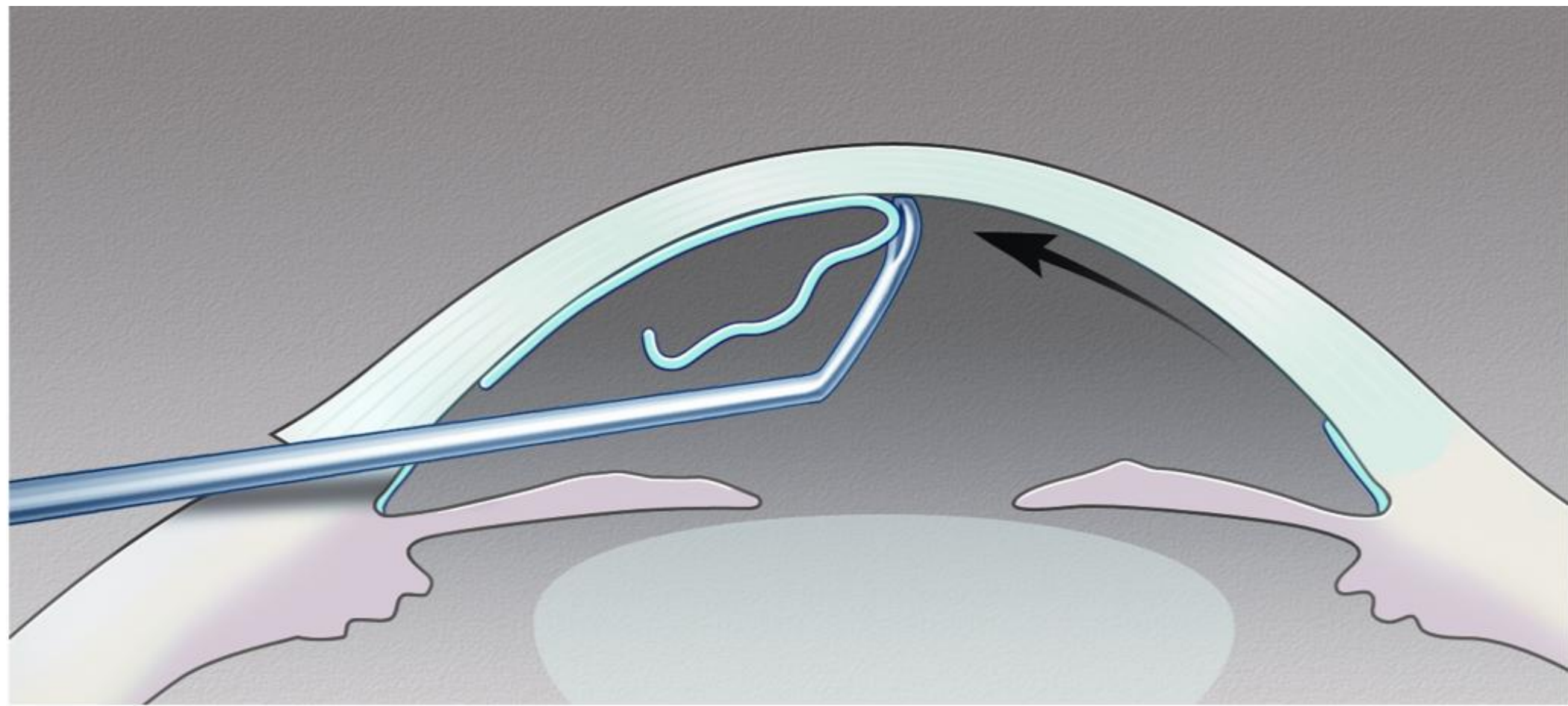


Figure 1 Different types of corneal transplant procedures



BLOOD INVESTIGATIONS

- Hb- 9.6 gm/dl
- RBCs- 3.13 M/cumm
- WBCs- 4,200 M/cumm
- DLC: N-69, L-28, E-2, M-1
- ESR- 70 mm (0-30 mm/hr)
- Platelet- 2.62 Lac
- PBS- Microcystic, hypochromic
- RFT- WNL
- LFT- WNL
- S.Electrolytes- WNL
- CRP- Negative
- PT/INR- 17/1.11 sec
- BT/CT- 3.3/4.2 min
- T.Protein- WNL
- HBsAg - +ve
- Blood group- AB +
- Urine examination- WNL
- BSL F/PP1/PP2- WNL

ULTRASOUND B SCAN

(RE)

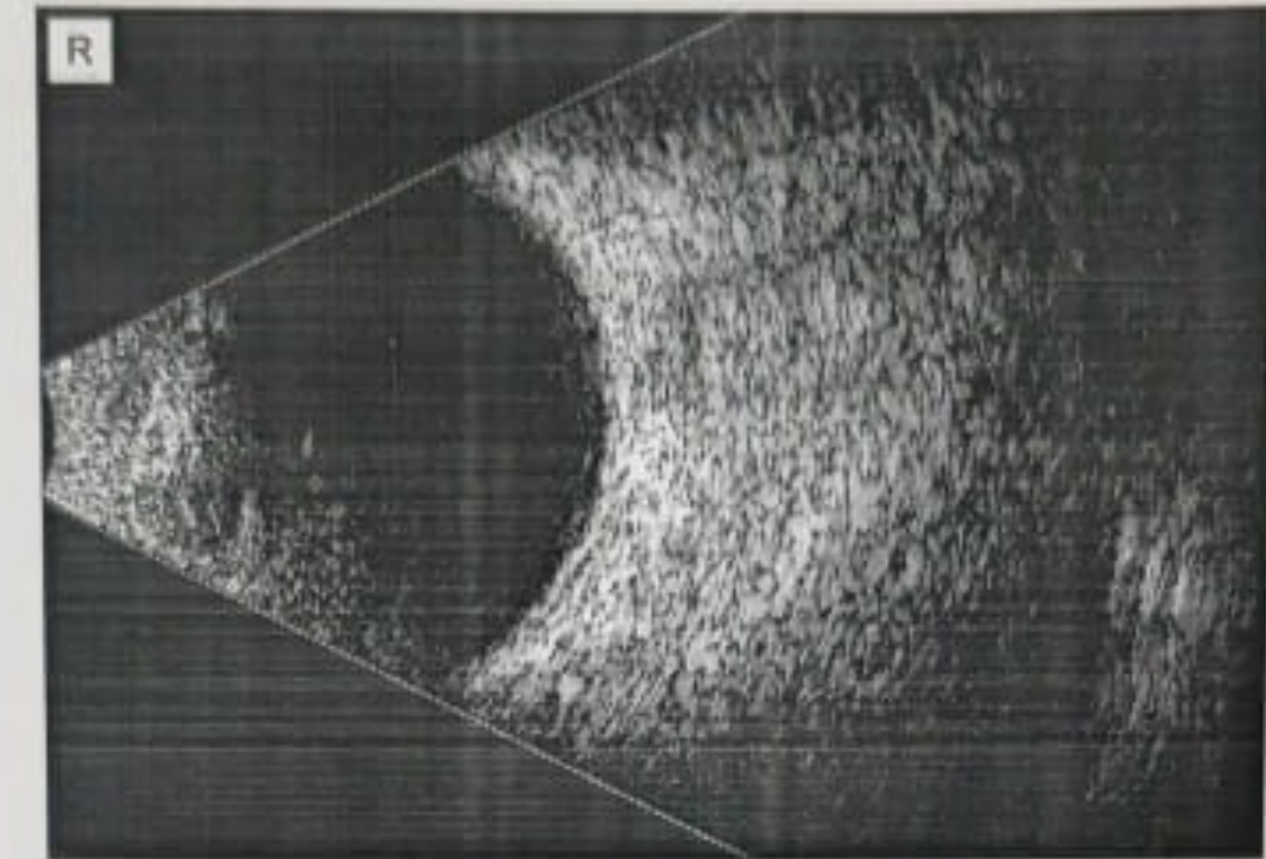
PC- INTACT

ONH- WNL

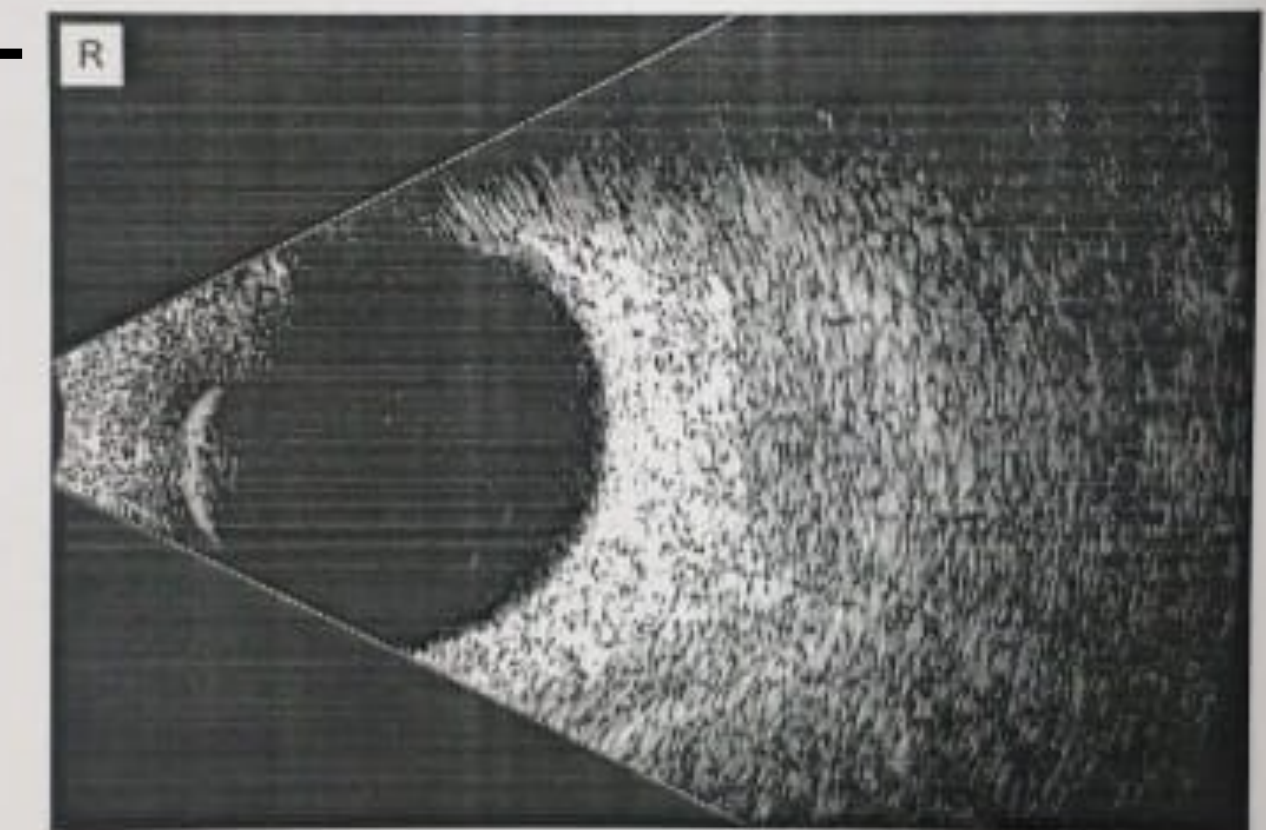
VITREOUS DEGENERATION

RETINA ATTACHED

AXIAL VIEW

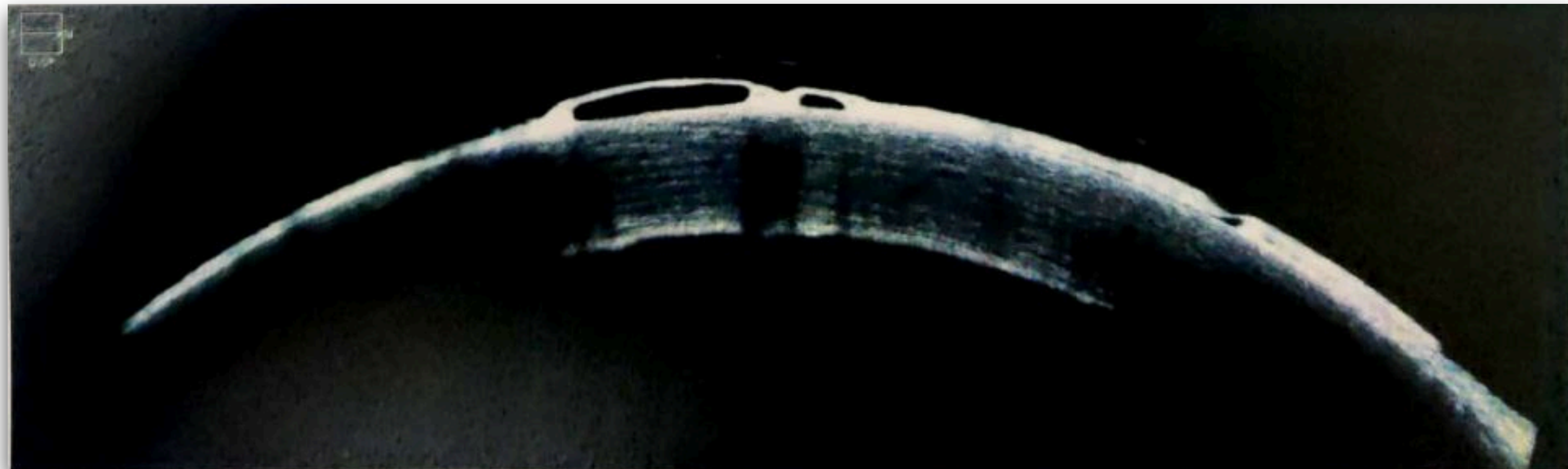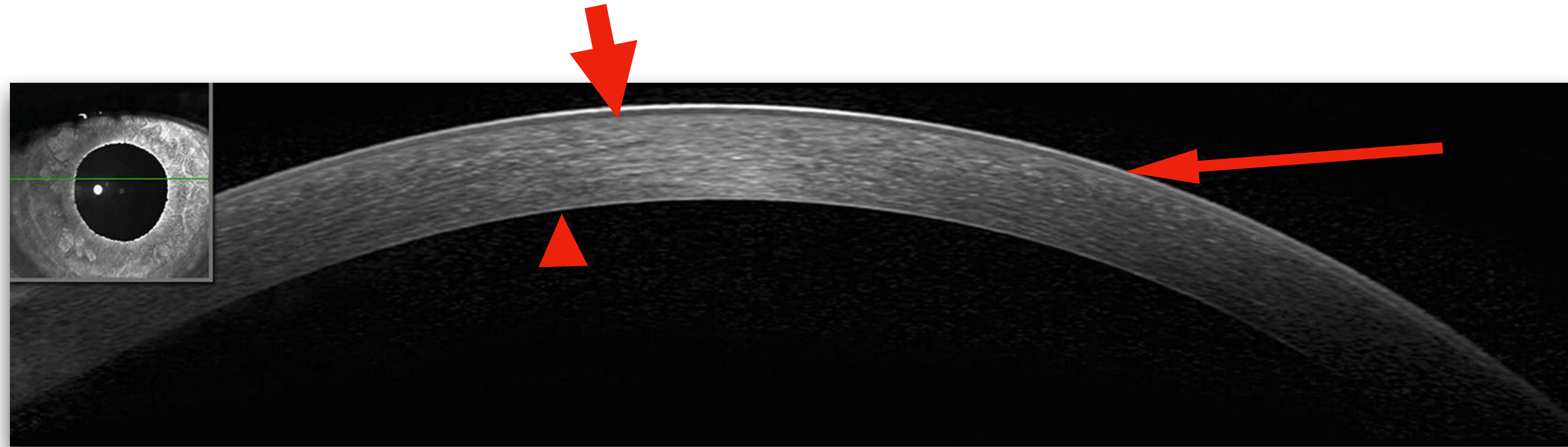


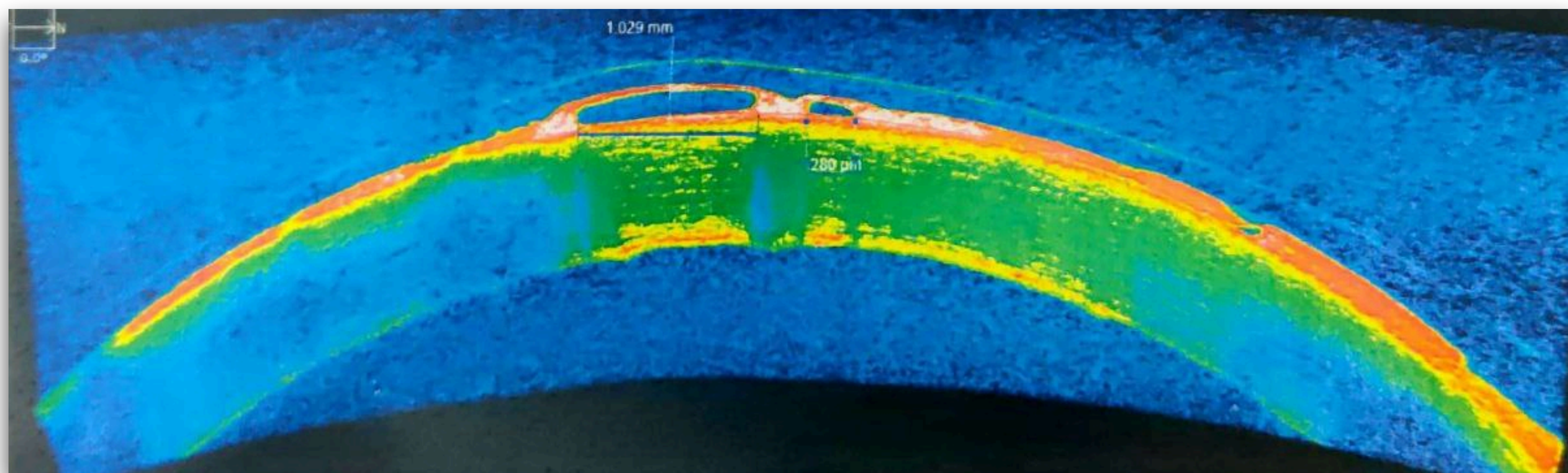
TEMPORAL
VIEW



Case Description:

PRE OP OPTICAL COHERENCE TOMOGRAPHY





POST OPERATIVE CARE

MEDICATIONS GIVEN: (RE)

E/D GATIFLOXACIN 3mg/ml + PREDNISOLONE 10mg/ml QID
(tapered accordingly)

E/D BRIMONIDINE 1.5mg/ml TID

E/D CARBOXY METHYLCELLULOSE 2 hourly

E/O HYDROXYPROPYL METHYLCELLULOSE HS

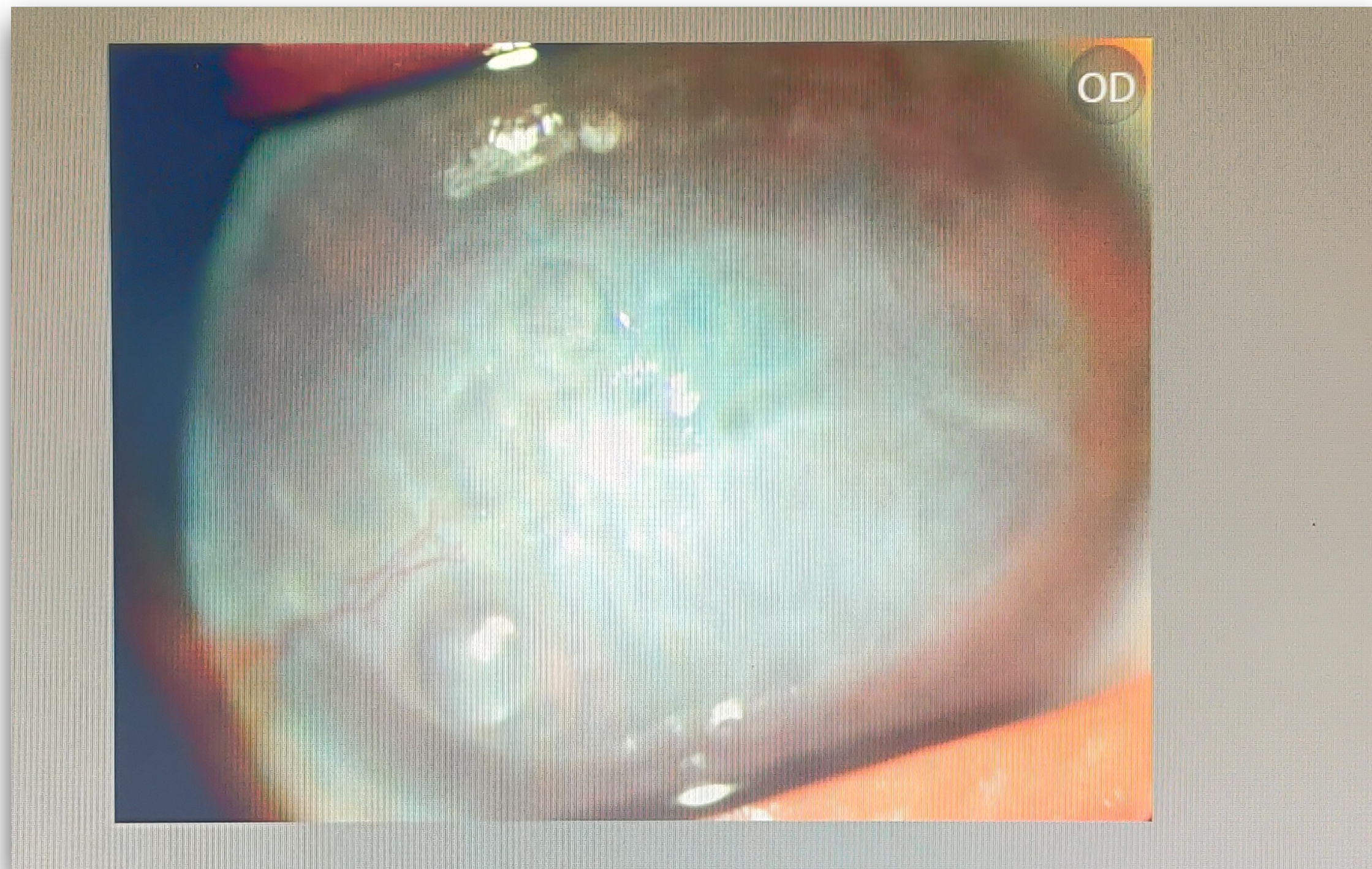
IV INJ DEXAMETHASONE 6mg BD

ORAL Antibiotics, analgesic, multivitamins given

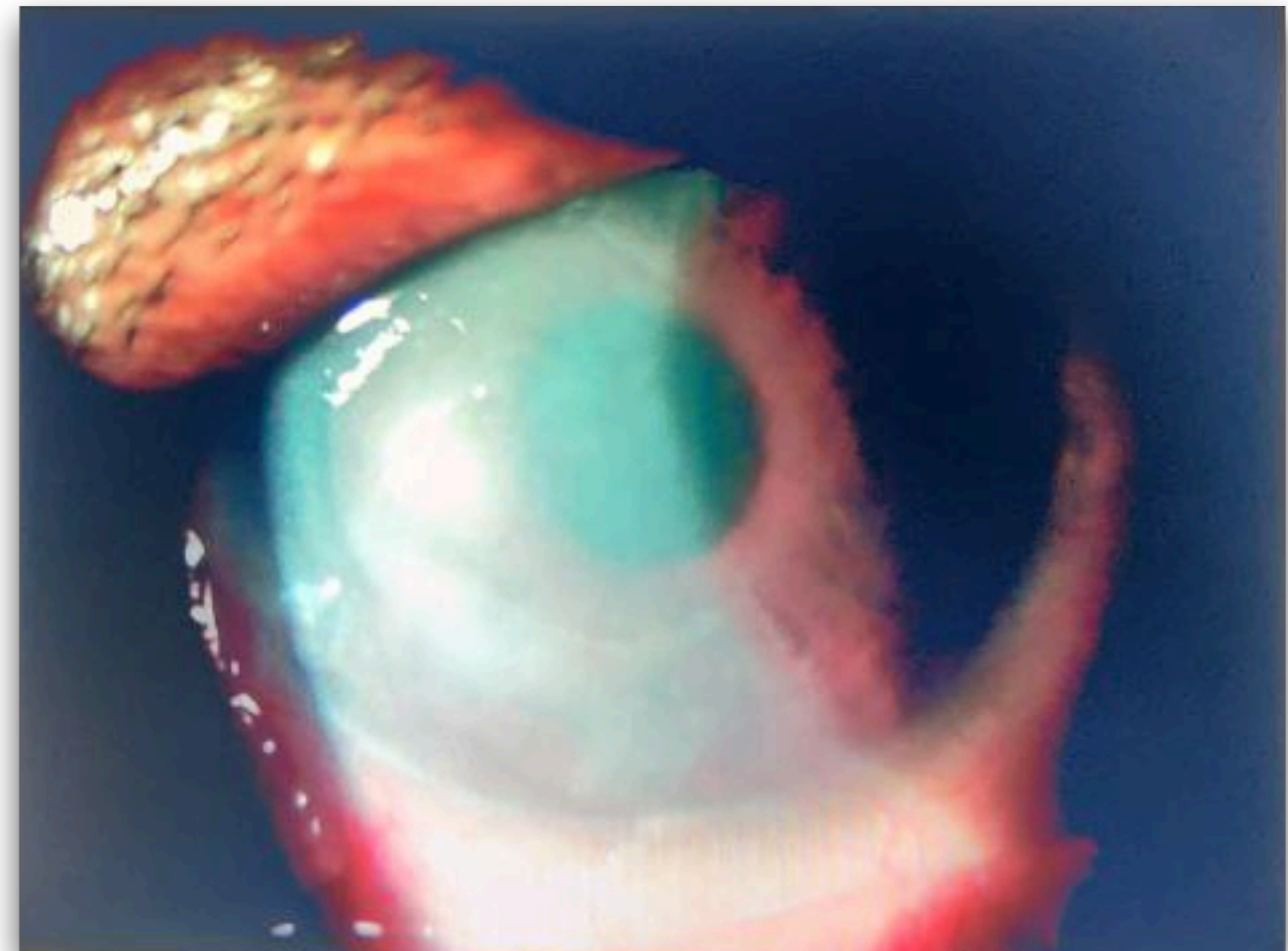
POD3

VISION: FINGER COUNTING AT 1 FEET

PRE OP

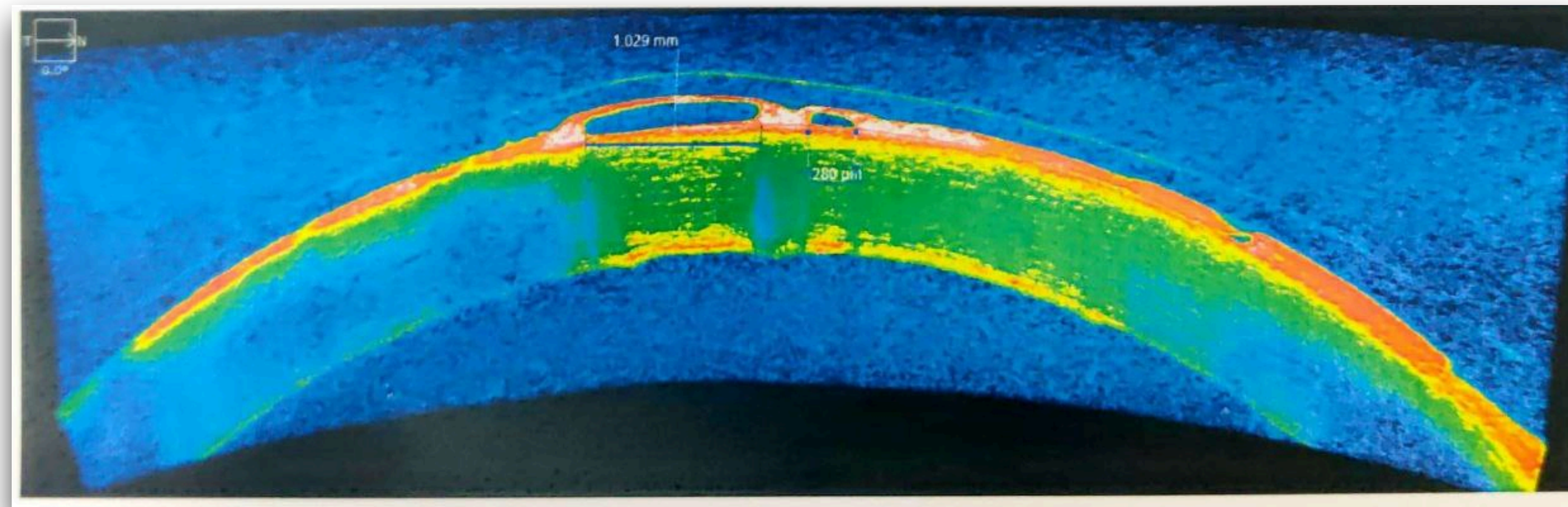


POD3



POD3 OCULAR COHERENCE TOMOGRAPHY

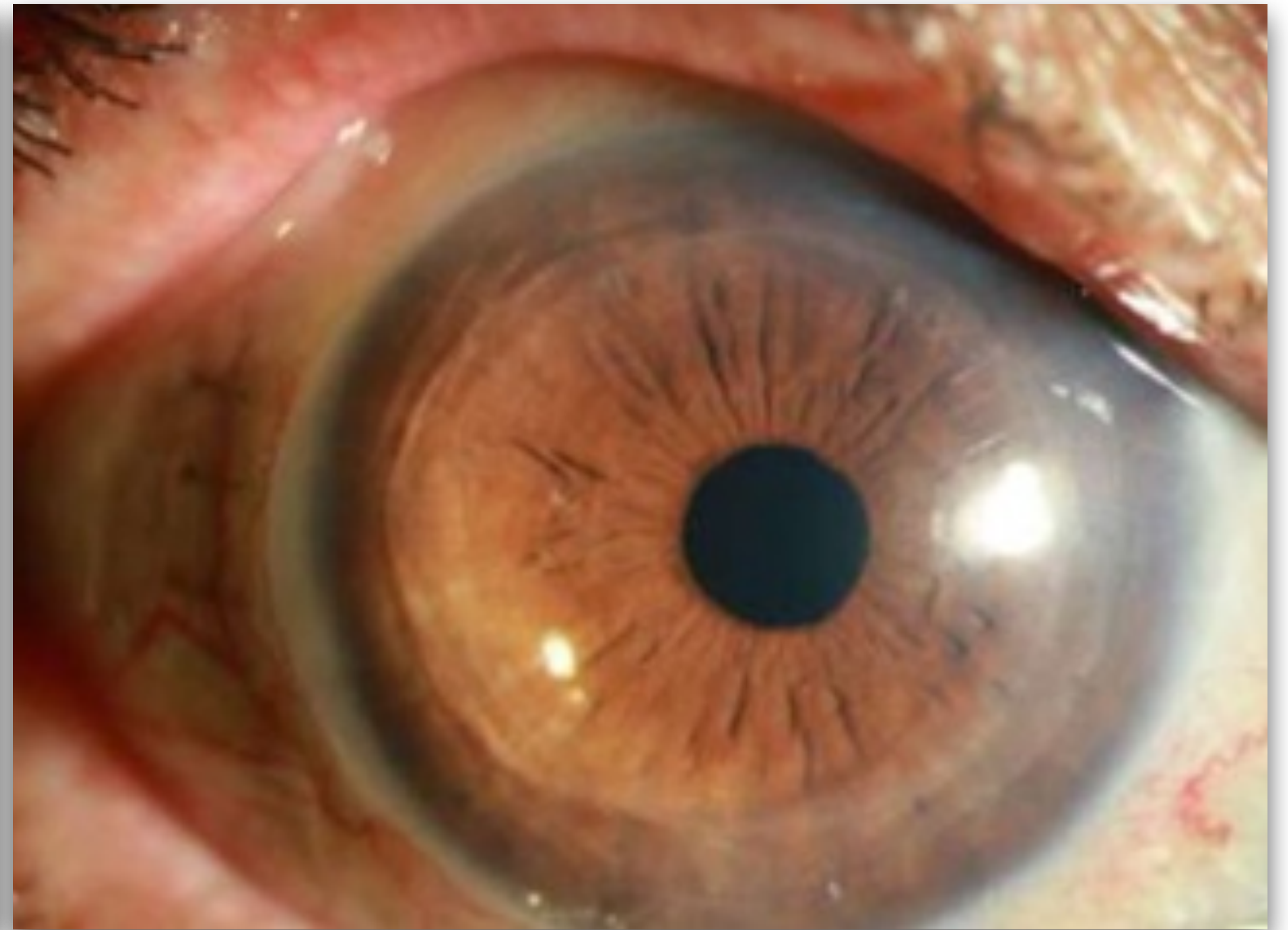
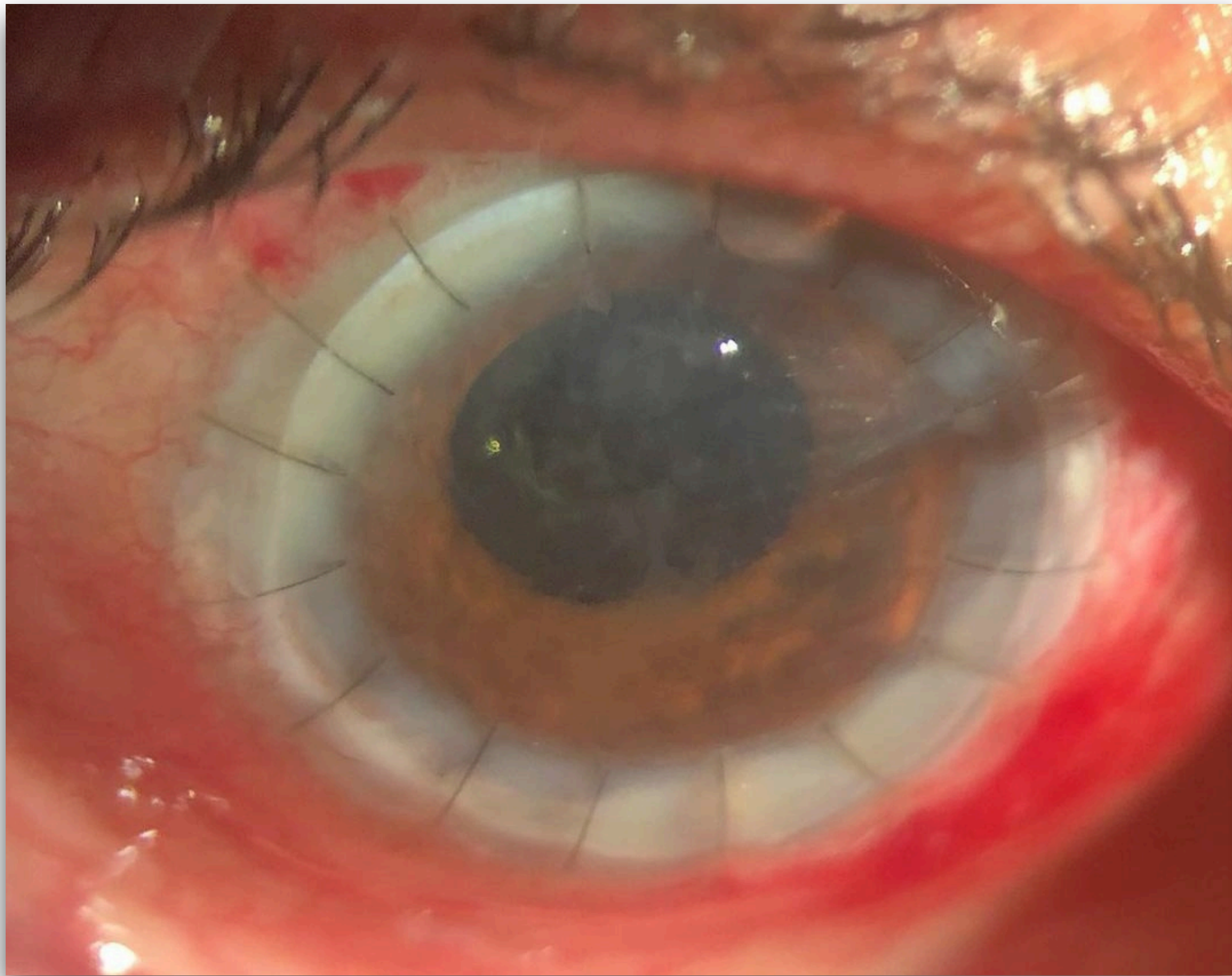
PRE OP



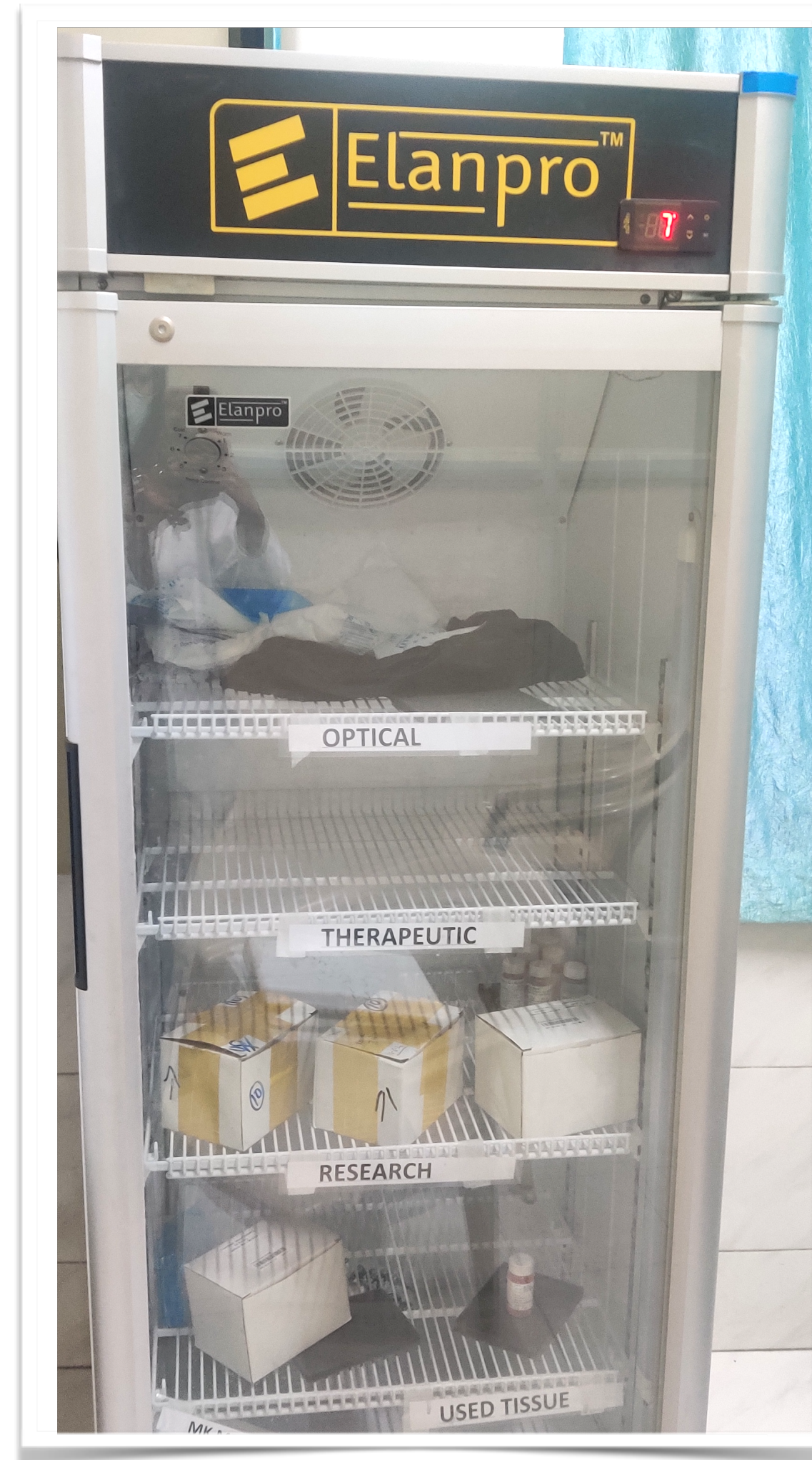
POD3



Total Penetrating Keratoplasty vs DSEK



EYE BANK



THANK YOU